

Complication of the use of bleomycin in the management of cystic craniopharyngioma: case report

José Roberto Tude Melo¹, Verônica Aline de Oliveira Barbosa², Leonardo Conrado Silva Lima¹, Paula de Almeida Azi³, José Henrique Silva Barreto⁴

¹ D'Or Institute for Research and Education (IDOR), Salvador da Bahia, Brazil and Pediatric Neurosurgery Unit, São Rafael Hospital, Rede D'Or - Salvador da Bahia, Brazil

² Radiology and Imaging Methods Service, São Rafael Hospital, Rede D'Or - Salvador da Bahia, Brazil

³ Pediatric intensive care unit, São Rafael Hospital, Rede D'Or - Salvador da Bahia, Brazil

⁴ Pediatric oncology service, São Rafael Hospital, Rede D'Or - Salvador da Bahia, Brazil

✉ José Roberto Tude Melo, MD

e-mail: robertotude@gmail.com

Available at:
<http://www.archpedneurosurg.com.br/>

Introduction/Background: Craniopharyngiomas are the most common neoplasms of the central nervous system of non-glial origin in childhood. Therapeutic options for proper management include total surgical resection, partial surgical resection associated with radiotherapy, and use of drugs such as bleomycin and alpha interferon (INF α) via Ommaya reservoir. The scope of this article is to report the case of a child with successive recurrence of craniopharyngioma who progressed to endocrine and neurological complications after bleomycin administration.

Case presentation: A 9-year-old boy underwent partial resections of craniopharyngioma followed by radiotherapy. Due to the increase in the cystic portion of the lesion, he underwent a complete treatment protocol with INF α . Two years after finishing the treatment, a new increase in the cystic portion of the craniopharyngioma was detected and bleomycin was administered in an attempt to control the disease. The boy was hospitalized on an urgent basis due to decreased level of consciousness, drowsiness, ataxia, and hyponatremia. Magnetic resonance imaging findings of the brain showed edema in the vicinity of the tumor suggestive of injury due to pharmacological toxicity. The child presented complete remission of symptoms with the use of systemic corticosteroids.

Conclusion: Neurotoxicity is a complication following bleomycin administration via Ommaya reservoir. Immediate discontinuation associated with the introduction of systemic corticosteroids and support in a specialized care unit can reverse the initial clinical picture.

Keywords: bleomycin, alpha interferon, pharmacological treatment, chemotherapy, craniopharyngioma.

INTRODUCTION


Corresponding to approximately 3% of intracranial tumors in childhood with the highest incidence between 5 and 15 years of age, craniopharyngiomas remain a challenge for the entire team involved in the treatment and management of this condition. The best therapeutic options, especially in younger children, include gross total resection (GTR), partial or subtotal resection (STR) associated with radiotherapy (RT), and intra-cystic application via Ommaya reservoir of bleomycin or alpha interferon (INF α) [1,2,3,4,5,6,7].

Faced with the challenge of establishing the best treatment for children with craniopharyngiomas, it is essential to know the various therapeutic options described in the literature and their possible complications [8,9,10,11]. This study aims to report clinical complications related to the use of bleomycin administered via the Ommaya reservoir in

a child diagnosed with relapsed adamantinomatous craniopharyngioma classified as presenting very high surgical risk according to the Paris [6] and Liverpool classifications [7].

CASE REPORT

A 9-year-old boy diagnosed with adamantinomatous craniopharyngioma discovered at the age of 3 due to acute hydrocephalus. At the time, he underwent urgent ventriculoperitoneal shunt (VP-shunt) in another hospital unit. He underwent three neurosurgical approaches seeking complete resection of the neoplasm, but only STR was possible in all attempts. After defining the impossibility of GTR due to the high degree of morbidity and risk of permanent hypothalamic dysfunction, RT was performed to a total dose of 5,400cGy. Later, he was referred for our multidisciplinary evaluation (pediatric neurosurgery, pediatric endocrinology, pediatric oncology, and



Complication of the use of bleomycin in the management of cystic craniopharyngioma: case report

ophthalmology). In the multidisciplinary evaluation we identified the presence of diabetes insipidus, hypothyroidism, hypocortisolism (panhypopituitarism with deficiency of adrenocorticotrophic hormone/ACTH, thyroid stimulating hormone/TSH, and antidiuretic hormone/ADH), obesity and visual deficit in the left eye. The child was on regular use of desmopressin (DDAVP 10 mcg/day), prednisolone (4.5 mg/day), and levothyroxine (25 mcg/day).

Approximately 1 year after RT, during the outpatient follow-up, an increase in the cystic portion of the tumor was observed in magnetic resonance imaging (MRI) of the brain (Figure 1), which was discussed in a multidisciplinary way among the pediatric oncology, neuroradiology and pediatric neurosurgery teams, and the option adopted was the implantation of an Ommaya reservoir catheter to start treatment with INF α . The therapeutic choice was based on the fact that it was a craniopharyngioma classified with very high surgical risk, according to the Paris and Liverpool classifications. INF α applications were performed on an outpatient basis by the pediatric oncology team for a mean period of 09 cycles, with 12 applications per cycle (3,000,000 IU on alternate days), with an interval of one month between cycles. Periodic imaging examinations (MRI of the sellar region) were performed quarterly to monitor the response to treatment. The child completed INF α treatment uneventfully.

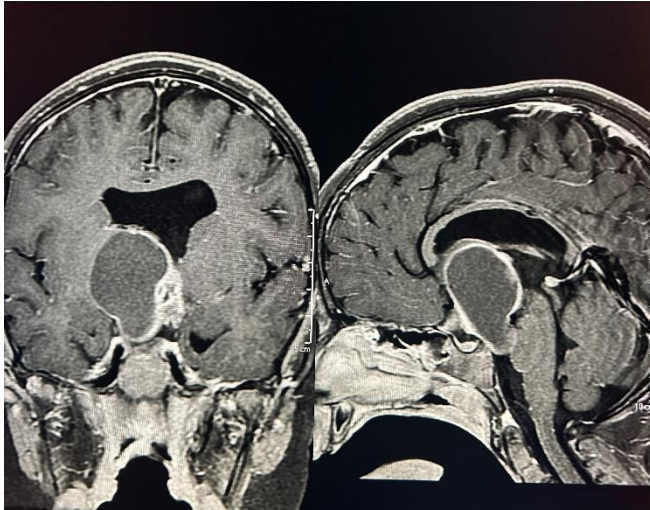


Figure 1- Magnetic resonance imaging of the brain (GE 1.5 Tesla) on contrast-enhanced T1-weighted (axial and sagittal) sequence showing sellar and suprasellar solid-cystic lesion approximately one year after three subtotal surgical resections and radiotherapy.

Approximately 02 years after the end of the use of INF α , an increase in the tumor was identified resulting from the expansion of the cystic portion and change of the characteristics of the residual lesion on MRI, and the pediatric oncology team opted for administering bleomycin via the Ommaya reservoir (Figure 2) in an attempt to control the progression of the disease. In the first cycle of bleomycin, the child reported malaise, with no other complaints. Fifteen

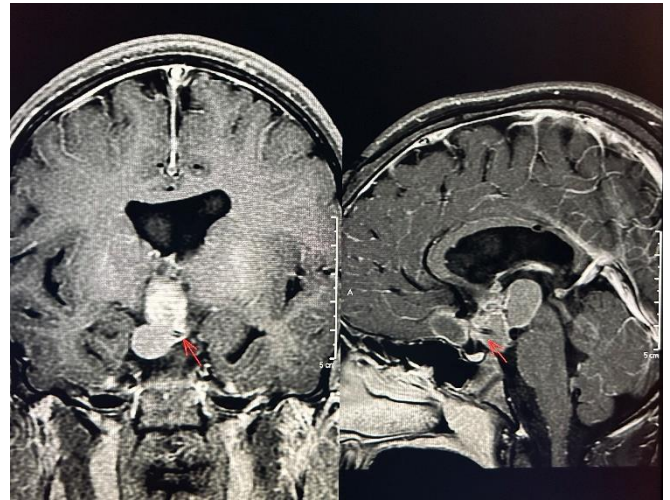


Figure 2- Magnetic resonance imaging of the brain (GE 1.5 Tesla) on contrast-enhanced T1-weighted (axial and sagittal) sequence showing a new increase in the solid-cystic sellar and suprasellar image accompanied by a change in the image signal approximately two years after the use of alpha interferon via the Ommaya catheter reservoir. The tip of the arrow indicates the positioning of the catheter.

days after the second cycle, the child started to have behavioral changes, drowsiness and gait ataxia. He was hospitalized and submitted to urgent MRI of the brain, in which we identified an extensive area of signal alteration compromising the regions thalamus, internal capsules, midbrain regions and part of the pons (Figure 3).

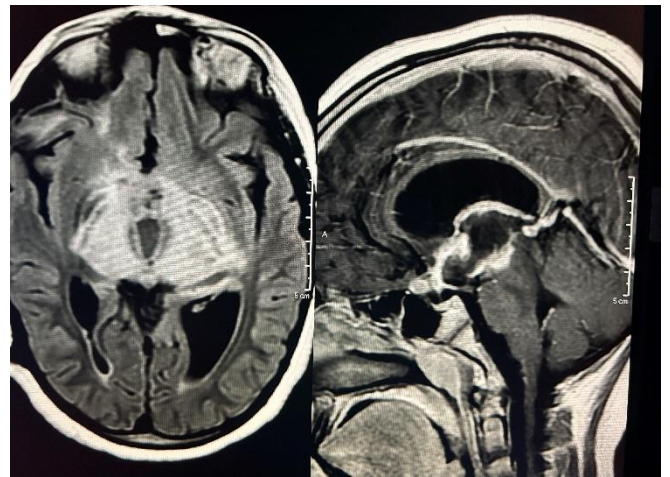


Figure 3- Magnetic resonance imaging of the brain (GE 1.5 Tesla) on contrast-enhanced T1-weighted axial Flair and sagittal sequences after administration of bleomycin via the Ommaya reservoir showing an imaging change of the signal hyperintensity type on the Flair, compromising the thalami, posterior arms of the internal capsules up to part of the midbrain and pons. The contrast-enhanced T1-weighted sagittal sequence shows an increased area of enhancement by gadolinium along the suprasellar solid-cystic lesion.

The child was maintained in the pediatric intensive care unit (PICU) and intravenous administration of systemic corticosteroids (dexamethasone) at 0.4 mg/kg/day (16mg/day) was immediately started, which was replaced 24 hours after initiation by hydrocortisone at a dose of

Complication of the use of bleomycin in the management of cystic craniopharyngioma: case report

100mg/m²/day or 3 mg/kg/day (stress dose for patients on chronic corticosteroid use) due to the parent's report of psychomotor agitation and hyperglycemia caused by the use of dexamethasone on a previous occasion. Optimization of serum sodium (initial concentration of 130 mmol/L) was performed, associated with management of diabetes insipidus with DDAVP and adjustment of blood volume. Twenty-four hours after starting the therapeutic measures, the child started to show improvement in the lowered consciousness, and within 48 hours he was already completely awake. The systemic corticosteroid dose was reduced at the fifth day to 50 mg/m²/day, and maintained until hospital discharge. The child showed complete improvement of symptoms after 7 days of systemic corticosteroid use, being discharged after this period without additional neurological deficits. At hospital discharge, the reduction of the dose of the corticosteroid within 3 days and subsequent maintenance of the basal dose were prescribed.

Follow-up brain MRI approximately 4 months after hospital discharge and discontinuation of bleomycin showed a significant reduction in the areas in which signal alteration had been previously identified, as well as a reduction in the volume of the lesion (Figure 4). The child is regularly followed-up by a multidisciplinary team with pediatric expertise in neurosurgery, endocrinology, oncology, and ophthalmology.

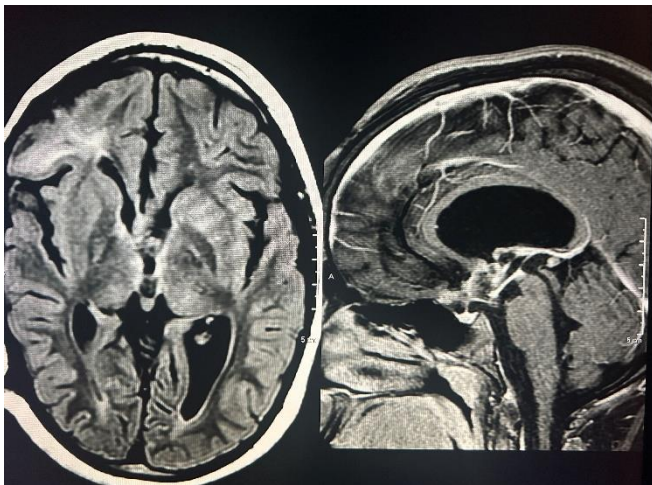


Figure 4- Magnetic resonance imaging of the brain (on contrast-enhanced T1-weighted axial Flair and sagittal sequences) (GE 1.5 Tesla) showing a significant reduction in areas with previously identified signal changes, in addition to the reduction in the volume of the solid-cystic lesion after the use of bleomycin via Ommaya reservoir.

DISCUSSION

Craniopharyngiomas are primary tumors of the sellar region, encapsulated and usually mixed (with solid and cystic portions), considered benign from a histopathological point of view and originating from embryonic remnants of the Rathke's pouch. They are non-gliar tumors characteristic of

childhood and adolescence whose management remains a challenge for the multidisciplinary teams involved in the treatment. Therapeutic options range from GTR, RT-associated STR, and intra-cystic application of bleomycin or INF α via Ommaya reservoir [1,2,3,4,5,6,7,8]. The decision on which treatment should be established is therefore aimed at preserving the hypothalamic-pituitary axis, since disastrous damage to this region can permanently compromise the quality of life of these children [3,6,7]. The case reported here was previously addressed through three surgical approaches (STR) and then referred to RT due to the impossibility of GTR, according to previously established protocols. Radiotherapeutic treatment is usually indicated in cases of STR with doses ranging between 4,500 and 5,500 cGy, especially in children over 5 years of age [3,8]. Multidisciplinary evaluation is essential in this group of patients. The exact moment of establishment of the neurological, endocrinological and ophthalmological deficits (pre/post-surgical or radiotherapeutic) could not be identified because the patient started to receive medical care from our team when he had already undergone three surgeries and RT, performed in an attempt to control the disease.

Craniopharyngioma recurrence is relatively frequent, posing the need to discuss new therapeutic alternatives [1,2,3,4,5]. Depending on the degree of resection, the rates in 10 years of local recurrence-free control vary between 57 and 89% in cases of RT-associated STR and between 31 and 42% in the absence of association with RT [8]. The assessment of surgical risk is fundamental for therapeutic planning, whether at the time of diagnosis or in the finding of recurrence and tumor growth. The Paris [6] and Liverpool [7] classifications are used to this end in our hospital practice, according to our previously published case series [3]. Both scales offer ease of application and help in decision making during the management of these patients [3,6,7]. Considering the clinical-endocrinological condition, in addition to the previously reported surgical difficulties and MRI findings, the case reported here was classified as presenting very high surgical risk, according to the said scales [6,7], and treatment with INF α was the alternative chosen. According to the literature on the administration of drugs via the Ommaya reservoir [3,5,9,10] and our own experience and previous publication (case series) of high- or very high-risk children with craniopharyngiomas [3], the use of INF α is recognized to present low complication rates, good tolerability, and satisfactory therapeutic responses. The child described here was not part of our previously published sample because he met the exclusion criteria adopted in that study [3].

The recurrence rate of craniopharyngioma, especially the increase in the cystic portion after application of INF α , is approximately 22% [5], which makes the search for treatment alternatives for this tumor incessant

Complication of the use of bleomycin in the management of cystic craniopharyngioma: case report

[1,2,3,4,5,6,10,11,12]. Usually used in squamous cell carcinomas, bleomycin is a drug that interferes with DNA production and leads to a decrease in the secretion of tumor fluid, producing tumor cell degeneration; its use even before INF α as an alternative in the management of craniopharyngiomas is described in the literature [1,4,11,12,13]. Adverse effects are described in 10 to 70% of cases, during or after the application of bleomycin through the Ommaya reservoir. The most common are headache, sometimes associated with nausea and/or vomiting, and transient episodes of fever [14]. Moderate and severe side effects are less frequent. Some examples such as blindness, drowsiness, seizure, panhypopituitarism, personality changes, thermal dysfunction, memory impairment, confusion, cerebral ischemia, and even death have been described in patients who received bleomycin applications [14,15,16]. In cases of neurotoxicity, the studies describe the possibility of identification of areas of vasogenic edema around the craniopharyngioma cyst by MRI, sometimes suggesting signs of drug extravasation, in addition to radiological signs suggestive of lesions in structures of the base of the brain, such as the hypothalamic region, optic pathways, brainstem, as well as the periventricular white matter and nuclei of the base of the brain [14,15,16], similar to the radiological findings reported in the clinical case described here.

Due to the relationship established between the onset of the symptoms described in the case reported here and the use of bleomycin, the team immediately decided to stop the use of the drug and admit the patient into the PICU with immediate initiation of systemic corticosteroid administration, as described in the literature [14]. Complete symptom improvement occurred after 7 days of systemic corticosteroid use, corroborated by follow-up imaging tests after hospital discharge, and the discontinuation of bleomycin was maintained. The child remains in regular multidisciplinary follow-up.

CONCLUSION

Neurotoxicity is a complication described in the literature after the application of bleomycin via the Ommaya reservoir, sometimes used for the management of craniopharyngiomas in childhood. Clinical suspicion needs to be confirmed by MRI, with characteristic radiological findings. Immediate cessation of drug use associated with introduction of systemic corticosteroids and support in a specialized unit (PICU) can completely reverse the initial clinical and radiological conditions.

DISCLOSURES

Ethical approval

Observational case report study approved by the Research Ethics Committee of São Rafael Hospital (CAAE 74827623.6.0000.0048, No. 6.506.146) with the consent and authorization of the legal guardians of the child, including authorization to disclose radiological images without identification of the child. The study was conducted ethically and in accordance with the Declaration of Helsinki

Consent to participate

The patients gave consent to use their information and images for research purposes. *Consent for publication*

The patient gave consent to use his information and images for publication.

Conflict of interest

The authors report no conflict of interest concerning the materials or methods used in this study or the findings specified in this paper.

Funding

This research received no specific grant from any funding agency in the public, commercial or not-for-profit sectors

CONTRIBUTIONS

-José Roberto Tude Melo: Conceptualization, Data curation, Formal Analysis, Funding acquisition, Investigation, Methodology, Project administration, Resources, Supervision, Validation, Visualization, Writing – original draft, Writing – review & editing

-Verônica Aline de Oliveira Barbosa: Funding acquisition, Investigation, Resources, Visualization, Writing – review & editing

-Leonardo Conrado Silva Lima: Funding acquisition, Resources, Visualization, Writing – review & editing

-Paula de Almeida Azi: Data curation, Funding acquisition, Investigation, Resources, Validation, Writing – review & editing

-José Henrique Silva Barreto: Data curation, Funding acquisition, Resources, Validation, Writing – review & editing

-: Data curation, Funding acquisition, Resources, Validation, Writing – review & editing

REFERENCES

Complication of the use of bleomycin in the management of cystic craniopharyngioma: case report

1. Tang AR, Haizel-Cobbina J, Khalid MU, Peter-Okaka UI, Prosak OL, Mushtaq N, Dewan MC. Global pediatric craniopharyngioma management modalities and outcomes. *Childs Nerv Syst.* 2024; 40: 47-56. doi.org/10.1007/s00381-023-06088-8.
2. Lohkamp LN, Kasper EM, Pousa AE, Bartels UK. An update on multimodal management of craniopharyngioma in children. *Front Oncol.* 2023; 13:1149428 doi.org/10.3389/fonc.2023.1149428.
3. Melo JRT, Santos FRPV, Barreto JHS, da Silva IC. Interferon-alfa in the management of cystic craniopharyngioma in children under 5 years of age. *Arch Pediatr Neurosurg.* 2021; 3: e662021. doi.org/10.46900/apn.v3i1(January-April).66.
4. Cavalheiro SC, Sparapani FVC, Franco JOB, da Silva MC, Braga FM. Use of bleomycin in intratumoral chemotherapy for cystic craniopharyngioma. *J Neurosurg.* 1996; 84: 124-126. doi.org/10.3171/jns.1996.84.1.0124.
5. Cavalheiro S, Di Rocco C, Valenzuela S, Dastoli P, Tamburrini G, Massimi L, Nicacio JM, Faquini IV, Ierardi DF, Silva NS, Pettorini L, Toledo SRC. Craniopharyngiomas: intratumoral chemotherapy with interferon- α : a multicenter preliminary study with 60 cases. *Neurosurg Focus.* 2010; 28 (4): E12, 2010. doi.org/10.3171/2010.1.FOCUS09310.
6. Puget S, Garnett M, Wray A, Grill J, Habrand JL, Bodaert N, Zerah M, Bezerra M, Renier D, Pierre-Kahn A, Sainte-Rose C. Pediatric craniopharyngiomas: classification and treatment according to the degree of hypothalamic involvement. *J Neurosurg.* 2007; 106: 3-12. doi.org/10.3171/ped.2007.106.1.3
7. Mallucci C, Pizer B, Blair J, Didi M, Doss A, Upadrasta S, Newman W, Avula S, Pettorini B. Management of craniopharyngioma: the Liverpool experience following the introduction of the CCLG guidelines. Introducing a new risk assessment grading system. *Childs Nerv Syst.* 2012; 28: 1181-1192. doi.org/10.1007/s00381-012-1787-8.
8. Veeravagu A, Lee M, Jiang B, Chang SD. The role of radiosurgery in the treatment of craniopharyngiomas. *Neurosurg Focus.* 2010; 28 (4): E11. doi.org/10.3171/2010.2.FOCUS09311.
9. Sharma J, Bonfield CM, Singhal A, Hukin J, Steinbok P. Intracystic interferon- α treatment leads to neurotoxicity in craniopharyngioma: case report. *J Neurosurg Pediatr.* 2015; 16 (3): 301-304. doi.org/10.3171/2015.2.PEDS14656.
10. Dastoli PA, Nicácio JM, Silva NS, Capellano AM, Toledo SRC. Cystic craniopharyngioma. *Arq Neuropsiquitr.* 2011; 69 (1): 50-55. doi.org/10.1590/S0004-282X2011000100011.
11. Steinbok P, Hukin J. Intracystic treatments for craniopharyngioma. *Neurosurg Focus.* 2010; 28 (4): E13. doi.org/10.3171/2010.1.FOCUS09315.
12. Jiang R, Liu Z, Zhu C. Preliminary exploration of the clinical effect of bleomycin on craniopharyngiomas. *Stereotact Funct Neurosurg.* 2002; 72 (2): 84-94. doi.org/10.1159/000068014.
13. Morantz RA, Kimler BF, Vats TS, Henderson SD. Bleomycin and brain tumors. *J Neuro-Oncol.* 1983; 1:249-255. doi.org/10.1007/BF00165609.
14. Lafay-Cousin L, Bartels U, Raybaud C, Kulkarni AV, Guger S, Huang A, Bouffet E. Neuroradiological findings of bleomycin leakage in cystic craniopharyngioma. report of three cases. *J Neurosurg.* 2007; 107(Suppl 4): 318-323. doi.org/10.3171/PED-07/10/318.
15. Belen D, Er U, Yigitkanli K, Bolay H. Delayed neurotoxic complications of intracavitary bleomycin therapy for craniopharyngioma in a child who had previously undergone radiosurgery. *J Neurosurg (5 Suppl Pediatrics).* 2007; 106: 391-393. doi.org/10.3171/ped.2007.106.5.391.
16. Cho WS, Kim SK, Wang KC, Phi JH, Cho BK. Vacuolopathy after bleomycin administration for a recurrent cystic craniopharyngioma. *J Neurosurg Pediatrics.* 2012; 9: 394-399. doi.org/10.3171/2012.1.PEDS11437.