



REVIEW ARTICLE

Anatomy of the ventricular system: Historical and morphological aspects

Roberto Alexandre Dezena, MD, PhD¹, Tareq A. Juratli, MD², Paulo Henrique Pires de Aguiar, MD³, Raphael Guerra David Reis, MD¹, João Pedro de Oliveira Jr., MD¹, Osei Yaw Nyarko, MD¹, Leonardo Noronha Queiroz Santos¹, MD, Pedro Henrique Simm de Pires de Aguiar, MD, PhD³

Received: 01 March 2020 / Published: 01 April 2020

Abstract

From the first description of the human ventricular system occurred in the 3rd century B.C. to modern neuronavigated endoscopy, neurosurgical knowledge evolved exponentially allowing safer approaches to the ventricular system. The present paper describes the historical aspects of ventricular system anatomy and its macroscopic and endoscopic anatomy from the Lateral ventricles to the third ventricle, describing in detail its structure and anatomical relationships.

Key words: Ventricular System; Anatomy; History; Lateral Ventricles; Third Ventricle; Neuroendoscopy

Historical aspects

Probably the first description of the human ventricular system may have occurred in the 3rd century B.C. by the Greeks Erasistratus (304 B.C. - 250 B.C.) and Herophilus (335 B.C. - 280 B.C.), who were authorized to perform dissections and vivisections in humans [1]. Claudius Galen (129 A.D.-217 A.D.) hypothesized that the ventricles were responsible for storing the animal spirit (pneuma psychikon). At the time, Galen, a gladiator physician, observed that traumatic injuries affecting the ventricles, never led to death, even if sensitivity and motor functions were affected [2,3]. From these ancient and empirical texts summoned with Catholic concepts, prevalent in the Dark Ages, the Cell Doctrine was established. This doctrine, which remained in vogue throughout the Dark Ages, tried to elucidate some aspects of brain physiology from the ventricles. What is known today as the lateral ventricles were considered as a single cavity, the first cell, in its anterior part, received external impulses and others from the rest of the body, characterizing common sense. In this same cell, in its posterior part, imagination and abstractions were generated. The second cell (the current third ventricle), was the site of production for cognitive processes such as reasoning, judgment and thought. The function of the posterior cell (the current fourth ventricle) would be to store all information [3-7]. Such concepts remained dogmatic until the Renaissance, when they began to be seriously questioned, from more precise anatomical descriptions. Curiously enough, until the Renaissance, there were only unexplained descriptions of Cell Doctrine. The great master of the Renaissance, Leonardo da Vinci (1452-1519) was the first to combine artistic expertise with profound anatomical knowledge. He represented the true transition and essence of the Renaissance spirit, as he created

¹ Division of Neurosurgery – Federal University of Triângulo Mineiro – Uberaba, Minas Gerais, Brazil

² Department of Neurosurgery – Faculty of Medicine Carl Gustav Carus – Technical University of Dresden – Dresden, Saachsen, Germany

³ School of Medicine – Pontifical Catholic University of São Paulo – Sorocaba, São Paulo, Brazil

To whom correspondence should be addressed: Roberto Alexandre Dezena, MD, PhD [E-mail: rdezena@yahoo.com.br]

illustrations of the Cell Doctrine and, in contrast, more accurate illustrations of the ventricular cavity [8-14] (Figs. 1 and 2). In 1543, the watershed of the history of anatomy emerged considered by many authors as the most important book in the history of science: *De humani corporis fabrica libri septem* or *De humani corporis fabrica*, or simply *Fabrica*, written by the Belgian, Andreas Vesalius (1514-1564), considered the "father of modern anatomy"[15]. His work contained incredible macroscopic anatomical details of the ventricles (Fig. 3). In 1663, the Dutch anatomist, Franz de le Boë (1614-1672) or Franciscus Sylvius in its Latinized form, also described the cerebral aqueduct [16]. Surprisingly, even after the precise descriptions of the Renaissance, the true content of the ventricular cavity, whether liquid or gaseous, remained in doubt. This was finally resolved in 1764 by the Italian Domenico Felice Antonio Cotugno (1736-1822), who discovered the cerebrospinal fluid. The description of the interventricular foramen occurred in 1783 and is credited to the Scot, Alexander Monro Secundus (1733-1817) [2]. The discovery of the communication between the ventricular cavity and the subarachnoid space was confirmed by French neurologist and experimental physiologist François Jean Magendie (1783-1855), in the medial region of the fourth ventricle, now known as foramen de Magendie or median opening of the fourth ventricle [17]. Other communication findings were made by the German anatomist Hubert von Luschka (1820-1875) in 1855, at the University of Tübingen. Such communications were known as lateral apertures of the fourth ventricle, or simply, foramen of Luschka [18]. Undoubtedly, the main descriptions of the ventricles and CSF system culminate with the work of Axel Key (1832-1901) and Magnus Gustaf Retzius (1842-1919). In this work, colored gelatin was injected into cadavers and showed that the gelatin flows through the granulations or villi arachnoids into the upper sagittal sinus [19].

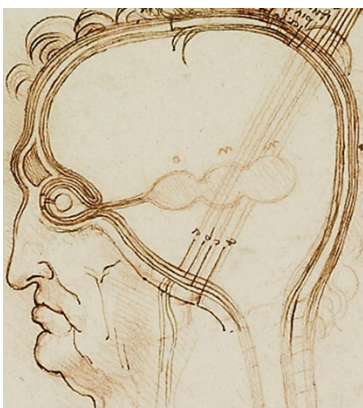

Fig. 1. "The Layers of the Scalp Compared with an Onion" (ca. 1490-1492). Still relying on the Cell Doctrine theory, Leonardo drew the brain in pen and ink according to the accepted notion of three cells, while the rest of the head was drawn realistically [12] (Image courtesy of History of Science Collections, University of Oklahoma Libraries).

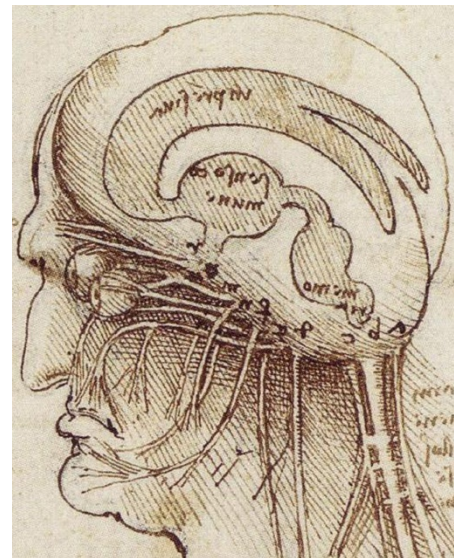


Fig. 2. "Study of brain physiology" (ca. 1508). Drawing in pen and ink by Leonardo after his study of ox brain injections. This rendering of the human brain, ventricles, visual pathways, and skull base reveals Leonardo's dissection experience and his break from traditional scholasticism, at least as far as personal experience and depiction are concerned [13,14] (Image courtesy of History of Science Collections, University of Oklahoma Libraries).

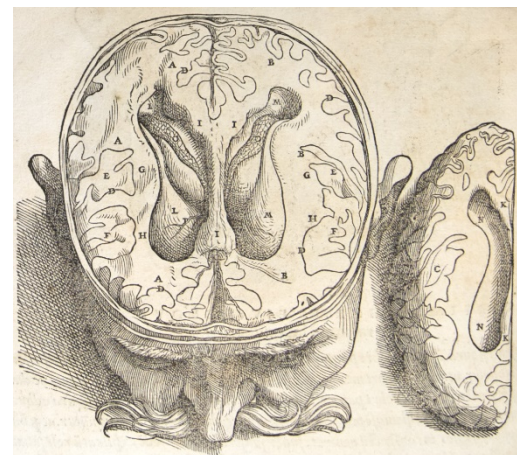

Fig. 3. The lateral ventricles from *Fabrica*, 1543 [15] (Image courtesy of History of Science Collections, University of Oklahoma Libraries).

Morphological aspects

Macroscopic anatomy

The ventricular system is divided into two lateral ventricles, third and fourth ventricles. The lateral ventricles unite with the third ventricle through the interventricular foramen or foramen of Monro, and the third ventricle joins with the fourth ventricle through the cerebral aqueduct or aqueduct of Sylvius. Each lateral ventricle has a frontal (anterior), body, atrium, occipital (posterior) and temporal (inferior) horn (Fig. 4), and each of these parts has a roof, floor, anterior, medial and lateral walls [20,21]. Such limits are found in Table 1. The third ventricle is a narrow midline cavity located in the center of the ventricular system. It communicates with the lateral ventricles through the

foramen of Monro in its anterosuperior aspect and with the cerebral aqueduct in its postero-inferior aspect.

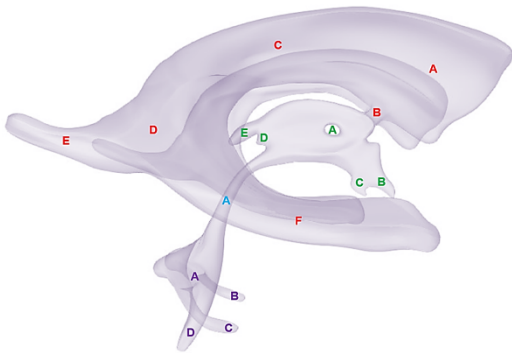


Fig. 4. The ventricular system in right lateral view. Lateral ventricle (in red): frontal horn (A), foramen of Monro (B), body (C), atrium (D), occipital horn (E), temporal horn (F). Third ventricle (in green): interthalamic adhesion (A), optic recess (B), infundibular recess (C), pineal recess (D), suprapineal recess (E). Cerebral aqueduct (in blue) (A). Fourth ventricle (in purple): fourth ventricle (A); left lateral recess and left lateral aperture of Luschka (B), right lateral recess and right lateral aperture of Luschka (C), median aperture of Magendie (D).

The roof of the third ventricle starts anteriorly at the foramen of Monro and ends posteriorly in the suprapineal recess. The roof is separated from the lateral wall by the choroidal fissure, which runs in the cleft between the upper part of the thalamus and the fornix. Over the anterior part of the roof, the fornices run in parallel and are often attached into the body of the fornix, whereas over the posterior roof, the fornices separate into the forniceal crura, and the roof is draped in interforniceal connecting white matter called the hippocampal commissure. However, the fornices and hippocampal commissure in the roof of the third ventricle are covered by a loose trabecular pial tissue that forms a double layer called tela choroidea. Between these two layers of tela choroidea is a space, the velum interpositum, through which the internal cerebral veins and the medial posterior choroidal arteries course [5]. The anterior half of the floor is formed by diencephalic structures and the posterior half by mesencephalic structures [20-22]. The structures that form the floor include, from anterior to posterior, the optical chiasm, the infundibular recess, the cinereal tubercle, the mammillary bodies, the posterior perforated substance and the tegment of the mesencephalon located above the medial aspect of the cerebral peduncles. The lateral walls are formed by the thalamus, the hypothalamus and the columns of the fornix. The posterior wall is formed from top to bottom by the suprapineal recess, the habenular commissure, the pineal body and its recess, the posterior commissure and the cerebral aqueduct [21,22]. The third ventricle limits are on Table 2. The fourth ventricle connects to the third ventricle through the cerebral aqueduct, and is located in its lowest portion. On the floor of the fourth ventricle is the limiting groove. This groove will separate the motor neurons, which will be located in a more medial

position, from the sensitive neurons that are located in a lateral position. The lateral portion to the limiting groove of the bulb and protuberance is mostly occupied by the vestibular nucleus and is generally referred to as the vestibular area. The medial area to the groove presents important structures such as the hypoglossal trigone, the vagal trigone and the vestibular nucleus. The fourth ventricle communicates with the subarachnoid space through the median or Magendie opening, and through the lateral or Luschka openings [22].

Endoscopic anatomy

The endoscopic ventricular anatomy is considered a mesoscopic anatomy, which is measured in millimeters, and is found in terms of size, between the macroscopic anatomy and the microscopic anatomy or histology [23]. Thus, mesoscopic anatomy is visualized both in neuroendoscopy and microsurgery. Endoscopic visualization presents some peculiarities, especially that it is not a three-dimensional modality. In addition, unlike microsurgery, endoscopy provides a wide angle of view and perspective when it reaches parts that would be optically hidden under the microscope [24,25], an effect called "fish-eye vision". Furthermore, in endoscopy, the size of the structures changes with the distance from the lenses, and a tiny vessel, when close to the lenses, can be twice the size of the main vessel. The use of irrigation during endoscopy constitutes an additional element for the production of flat images. Additionally, the geometry of microscopic vision is the opposite of endoscopic vision. While the former corresponds to a pyramid whose apex is at the depth of the operative field and its base is craniotomy on the surface, the geometry of endoscopic vision is inverted by the optics, thus creating a cone with the apex located at the tip of the neuroendoscope and the base appearing distant [26-27]. The microscopic view allows the surgeon to focus on the depth of field and use, concomitantly, the structures present along the dissection plane as an anatomical reference [27]. The endoscope lenses are located at the tip of the instrument and make available only the structures located in front of the lenses, but never along the instrument tube [27]. Therefore, as one progresses in the depth of the cavity, it is not possible to visualize the structures left behind unless the endoscope is mobilized. All these factors and limitations give unquestionable importance to the knowledge of the anatomy of the ventricular system [28]. For the vast majority of ventricular endoscopic surgeries, using rigid neuroendoscopy systems, knowledge of the anatomy of the lateral and third ventricles is of paramount importance [20].

Lateral ventricles

Each lateral ventricle is a "C" shaped cavity, which surrounds the thalamus and is situated deep in the

Table 1. Regions and limits of the lateral ventricle.

LATERAL VENTRICLE	ROOF	FLOOR	ANTERIOR WALL	MEDIALWALL	LATERAL WALL
FRONTAL HORN	Genu of the corpus callosum	Rostrum of the corpus callosum	Genu of the corpus callosum	Septum pellucidum Columns of the fornix	Head of the caudate nucleus
BODY	Body of the corpus callosum	Thalamus		Septum pellucidum Body of the fornix	Body of the caudate Nucleus Thalamus
ATRIUM	Body, splenium and tapetum of the corpus callosum	Collateral trigone	Crus of the fornix Pulvinar of the thalamus	Bulb of the corpus callosum Calcar avis	Tail of the caudate nucleus Tapetum of the corpus callosum
OCCIPITAL HORN	Tapetum of the corpus callosum	Collateral trigone		Bulb of the corpus callosum Calcar avis	Tapetum of the corpus callosum
TEMPORAL HORN	Thalamus Tail of the caudate Nucleus Tapetum of the corpus callosum	Hippocampus Collateral eminence	Amygdala	Choroidal fissure	Tapetum of the corpus callosum

Table 2. Regions and limits of the third ventricle.

ROOF	FLOOR	ANTERIOR WALL	POSTERIOR WALL	LATERAL WALL
Body and crus of the fornix, hippocampal commissure	Optic chiasm	Columns of the fornix	Suprapineal recess	Thalamus
	Infundibular recess	Foramen of Monro	Habenular commissure	Hypothalamus
Tela choroidea and vessels (medial posterior choroidal artery and interna cerebral vein)	Tuber cinereum	Anterior commissure	Pineal body and pineal recess	Columns of the fornix
	Mammillary bodies	Lamina terminalis	Posterior commissure	
	Posterior perforated substance	Optic recess		
	Tegmentum of the mesencephalon	Optic chiasm	Cerebral aqueduct	

brain, following the outline of the chorioid fissure. These structures represent, from the embryological point of view, the light of the telencephalic vesicles. Each lateral ventricle has five parts: frontal horn, body, atrium, occipital horn and temporal horn [29]. The frontal horn is the part of the lateral ventricle located anterior to the foramen of Monro. The lateral ventricle body extends from the posterior margin of this foramen to the point where the fornix and the corpus callosum meet, thus disappearing the pellucid septum. The atrium of the lateral ventricle and its occipital prolongation form a triangle with an anterior base in the pulvinar and a posterior apex in the occipital lobe. The occipital horn is triangular with a posterior apex and base in the atrium. The temporal horn is the inferior prolongation of the ventricle, being the continuation of the atrium, addressing anteriorly and laterally. Each of these divisions has a medial wall, lateral wall, ceiling and floor. In addition, the frontal,

temporal and atrial horns have anterior walls. These walls are formed by the thalamus, pellucid septum, white substance, corpus callosum, caudate nucleus and fornix [30-31]. The foramen of Monro varies in elliptical to circular form and communicates the lateral ventricle with the third ventricle. Its path, observed from the ventricular side, is tilted superior and medial and then inferior and lateral [32]. The size and shape of the foramen depend on the size of the ventricles: if the ventricles are small, each foramen is an opening in an increasing shape limited anteriorly by the concave curve of the fornix and posteriorly by the anterior convex tubercle of the thalamus. When the ventricles increase in size, the foramen on each side becomes rounder. Their approximate dimensions are 5x3 mm [33]. The plane of the foramen is oriented in such a way that a perpendicular axis is directed medial, ventral and caudal [34]. The foramen is not only a natural communication between the lateral

ventricle and the third ventricle, but it is a region in which structures converge, such as the coronoid plexus and important venous structures. The anatomical landmark that seems to be the most reliable to locate the foramen is the coronoid plexus, because the venous structures may be absent, not clearly visible or may vary considerably in their configuration, the number of tributaries or the place where they enter the choroid fissure to drain into the internal cerebral vein. The most prominent projections of the choroid plexus in the lateral ventricle are located in the temporal horn and atrium [33]. In the temporal horn it spreads laterally from its fixation in the upper region of the hippocampus. In the atrium, it forms a prominent triangular tuft called the choroid glomus, which can normally be prominent and suggest the presence of a neoplasm in radiological studies. In the margin of the thalamus and fornix there are small linear depressions, called tenia, in which the choroid plexus is adhered. The choroid plexus of the third ventricle is projected downwards from the ceiling of the third ventricle on each side of the midline plane. The lateral and third ventricle choroid plexus are supplied by the anterior choroidal artery and lateral and medial posterior choroidal branches. The anterior choroidal artery originates from the internal carotid artery and enters the temporal horn. The lateral posterior choroidal branches originate from the posterior cerebral artery and enter the temporal horn, atrium and central part of the lateral ventricle. The medial posterior choroidal branches originate from the posterior cerebral artery and enter the roof of the third ventricle. The intraoperative images demonstrated below have the Kocher's point as reference, located approximately 2 cm in front of the coronal suture and 2 cm lateral to the midline. This is the main access point to the ventricular system for endoscopic procedures [20]. For the lateral ventricle, the endoscopic viewing angle is shown and images of this region are shown in Figs. 5 to 12.

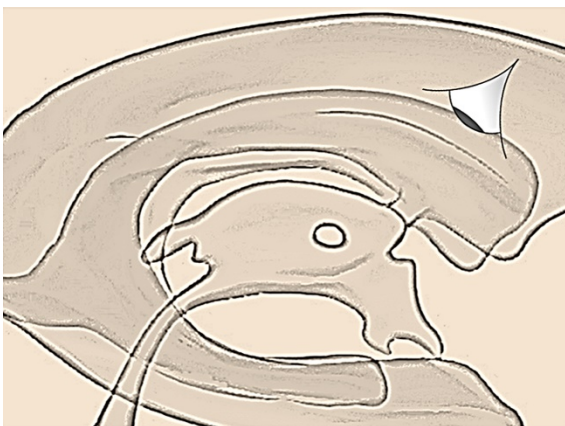

Fig. 5. Direction of the endoscopic viewing angle for foramen of Monro region.

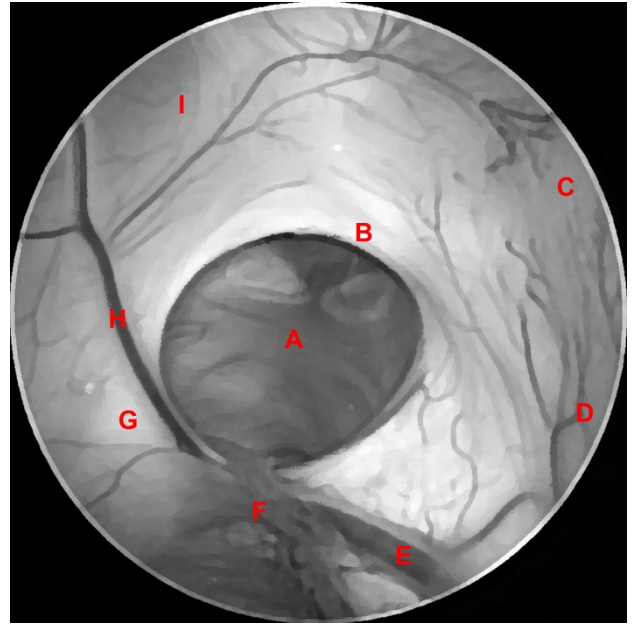


Fig. 6. Foramen of Monro (A), column of the fornix (B), frontal horn (C), head of the caudate nucleus (D), superior thalamostriate vein (E), choroid plexus (F), body of the fornix (G), anterior septal vein (H), septum pellucidum (I).

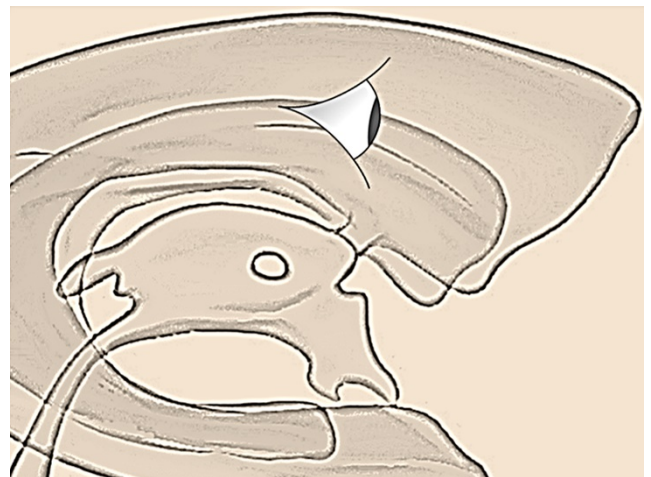


Fig. 7. Direction of the endoscopic viewing angle for frontal horn.

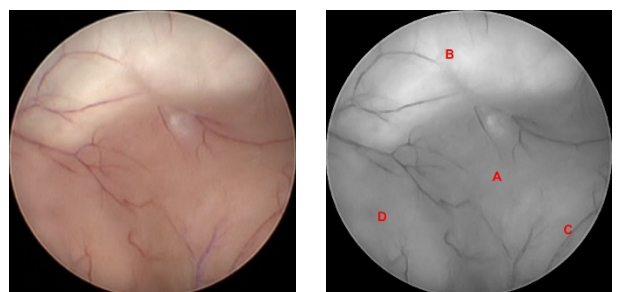


Fig. 8. Frontal horn (A), genu of the corpus callosum (B), head of the caudate nucleus (C), septum pellucidum (D).

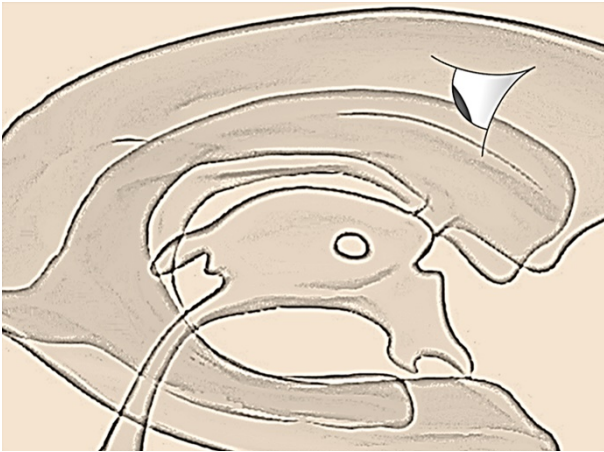


Fig. 9. Direction of the endoscopic viewing angle for ventricular body.

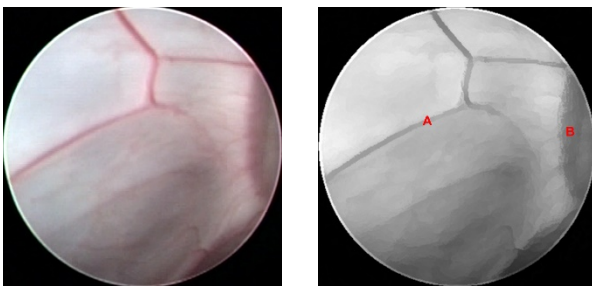


Fig. 10. Septal veins (A), anterior septal vein (B).

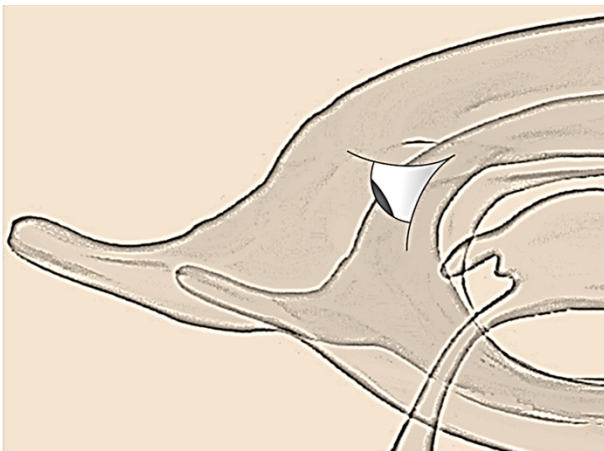


Fig. 11. Direction of the endoscopic viewing angle for ventricular atrium.

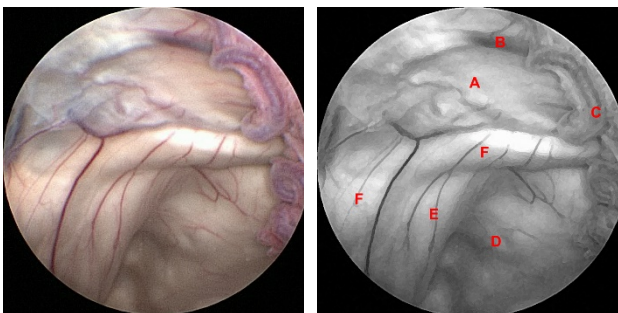


Fig. 12. Septum pellucidum (A), posterior septal vein (B), superior choroidal vein (C), collateral eminence (D), calcar avis (E), bulb of the occipital horn (F).

Third ventricle

The third ventricle is a funnel-shaped, unilocular narrow midline cavity. Under normal conditions, it's practically a slit. It communicates at the anterosuperior margin with each lateral ventricle through the foramen of Monro and later with the fourth ventricle through the cerebral aqueduct. In adult individuals, the lateral-lateral distance of the third ventricle is 5.5 mm on average [35]. In a study using MRI, the hydrocephalic configuration of the third ventricle disappeared after an endoscopic third ventricle, with a decrease in the diameter, elevation and horizontal direction of the floor and a decrease in the infundibular angle [36]. The floor of the third ventricle extends from the optic chiasm anteriorly to the opening of the cerebral aqueduct posteriorly. It descends ventral and is formed by at least 12 cellular groups or nuclei within the hypothalamic region [37]. Anatomically, there are three portions on the floor of the third ventricle: pre-mammillary portion, which extends from the infundibulum to the pre-mammillary sulcus, constituting a very thin layer of gray substance of the hypothalamus; interpeduncular portion, which extends from the post-mammillary recess to the posterior margin of the interpeduncular space, being formed of gray substance and firmer than the first; peduncular portion, which corresponds to the portion of the cerebral peduncles, the most solid portion being formed by the medial aspect of the peduncles covered by the peduncular ependyma [38]. The anterior half of the floor is formed by the diencephalic structures, and the posterior half by the mesencephalic structures. The infundibulum of the hypothalamus is a hollow, funnel-shaped structure, located between the optic chiasm and the cinereal tuber, with a reddish-yellow coloration, which corresponds to the implantation of the pituitary stem in the floor [27]. The pituitary gland is connected to the infundibulum, and the axons of the infundibulum extend to the posterior part of the gland. When the third ventricle is observed superiorly and internally, the optical chiasm forms a transverse eminence in the anterior margin of the floor [34,39]. The infundibulum recess extends into the posterior infundibulum of the optic chiasm, an area slightly orange or reddish [40], which corresponds to the implantation of the pituitary stem. The floor between the mammillary bodies and the cerebral aqueduct has a smooth surface that is concave from one side to the other. This surface covers the posterior perforated substance, anteriorly, and part the medial of the cerebral peduncles and tegment of the mesencephalon, posteriorly. The most important anatomical references on the floor for endoscopic third ventriculostomy are the dorsum of the sella turcica and the pulsating basilar artery, as well as the mammillary bodies and the infundibulum [41]. As long as the distance between the mammillary bodies and the infundibulum recess is 6 mm, there is ample space for a safe endoscopic third ventriculostomy [42]. In

hydrocephalic patients, the floor of the third ventricle may be elevated to the level of the infundibulum recess compared to the mammillary bodies and, for this reason, the puncture of the third ventricle floor may be difficult [40]. The tuber cinereum is a prominent mass of hypothalamic gray substance located anterior to the mammillary bodies, which fuses anteriorly with the infundibulum. The region of the tuber cinereum around the base of the infundibulum is elevated, forming a prominence called the median eminence of the hypothalamus. Laterally, the tuber cinereum is delimited by the optic tracts and cerebral peduncles [43]. When viewed by the endoscope from the third ventricle, the tuber cinereum is translucent and dark blue, while the infundibulum recess is light red. The tuber cinereum is demonstrable not only posterior but also anterior to the optic chiasm [44]. The blood supply to the tuber cinereum originates from the lower diencephalic branches in number one to ten, mainly the posterior communicating artery [45] and the internal carotid artery [44,46]. The mammillary bodies form round prominences, posteriorly to the tuber cinereum. In the hypothalamus, the mammillary bodies are the only nuclei identified in the MRI [37]. They are spherical structures, approximately 5 mm in diameter, located inferiorly in the brain at the posterior limit of the hypothalamus. They are composed of two nuclei, a more prominent medial and a lateral one [47]. In endoscopic terms, the third ventricle can be divided into anterior, middle and posterior segments [20] (Fig. 13). Knowledge of the endoscopic anatomy of the anterior segment of the third ventricle is of paramount importance for performing endoscopic third ventriculostomy [48]. The middle segment usually presents the interthalamic adhesion, which may be more or less prominent depending on the patient's age, being more present in children. Knowledge of the posterior segment anatomy is useful for endoscopic procedures such as aqueductoplasty and tumor biopsies. For regions of the third ventricle, the endoscopic viewing angle is shown and images of this region are shown in Figs. 14 to 19.

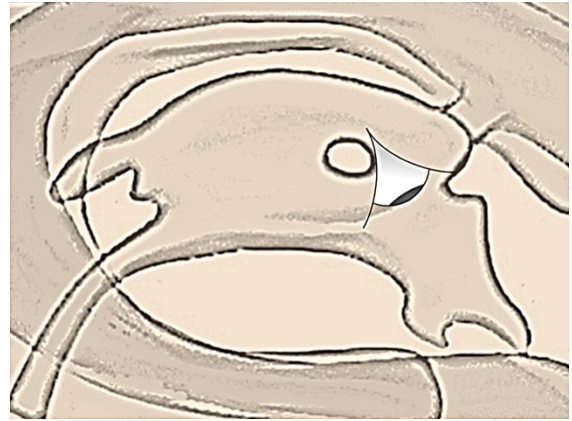


Fig. 14. Direction of the endoscopic viewing angle for the anterior segment of the third ventricle.

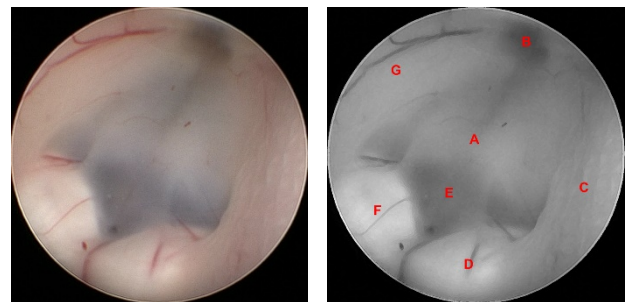


Fig. 15. Tuber cinereum (A), infundibular recess (B), right hypothalamus (C), right mammillary body (D), premammillary recess (E), left mammillary body (F), left hypothalamus (G).

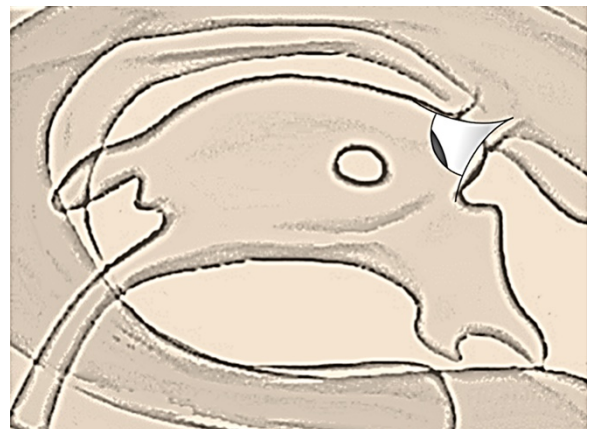


Fig. 16. Direction of the endoscopic viewing angle for the middle segment of the third ventricle.

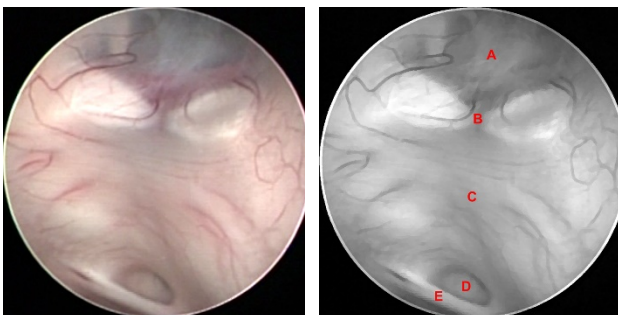


Fig. 13. Tuber cinereum (A), mammillary bodies (B), middle segment (C), cerebral aqueduct (D), posterior commissure (E).

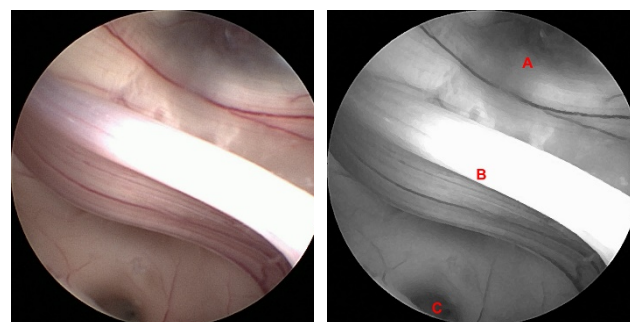


Fig. 17. Postmammillary recess (A), interthalamic adhesion (B), cerebral aqueduct entrance (C).

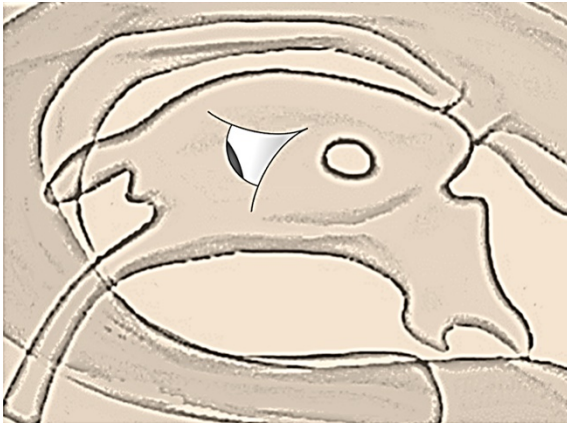

Fig. 18. Direction of the endoscopic viewing angle for the posterior segment of the third ventricle.

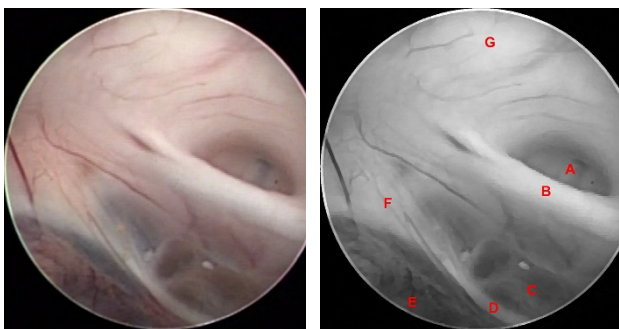


Fig. 19. Cerebral aqueduct entrance (A), posterior commissure (B), pineal recess and pineal gland (C), habenular commissure (D), suprapineal recess (E), habenular trigone (F), left thalamus (G).

References

1. Von Staden H. Herophilus: the art of medicine in early Alexandria. New York: Cambridge University Press; 1989.
2. Mortazavi MM, Adeeb N, Griessenauer CJ, Sheikh H, Shahidi S, Tubbs RI, et al. The ventricular system of the brain: a comprehensive review of its history, anatomy, histology, embryology, and surgical considerations. *Childs Nerv Syst.* 2014;30:19–35. doi:10.1007/s00381-013-2321-3
3. Gross CG. Brain, vision, memory: tales in the history of neuroscience. Cambridge: MIT Press; 1998.
4. Tascioglu AO, Tascioglu AB. Ventricular anatomy: illustrations and concepts from antiquity to Renaissance. *Neuroanatomy.* 2005;4:57–63.
5. Telfer W. Cyril of Jerusalem and Nemesius of Emesa. Philadelphia: Westminster Press; 1955.
6. Corner GW. Anatomical texts of the earlier middle ages: a study in the transmission of cultures. Washington: Carnegie Institute of Washington; 1927.
7. Reisch G. Margarita philosophica. Freiburg: Schott; 1503.
8. Woolam DMH. Concepts of the brain and its functions in classical antiquity. In: Poynter FNL, editor. The history and philosophy of knowledge of the brain and its function. Springfield: Thomas; 1958. p.48–75.
9. Singer CJ. A short history of anatomy from the Greeks to Harvey. 2nd ed. New York: Dover Publications; 1957.
10. McMurrich JP. Leonardo da Vinci the anatomist. Baltimore: Williams and Wilkins; 1930.
11. Clayton M. Leonardo da Vinci: the anatomy of man. Boston: Little, Brown and Company; 1992.
12. Vinci L, Vangensten OCL, Fonahn A, Hopstock H. Quaderni di anatomia. Christiania: Jacob Dubwad; 1911-1916.
13. Ariès P. The hour of our death. New York: Knopf; 1981.
14. Peccatori S, Zuffi S. Piero della Francesca. London: Dorling Kindersley; 1999.
15. Vesalius A. De humani corporis fabrica libri septem. Basel: Johannes Oporinus; 1543.
16. Santos ARL, Fratzoglou M, Perneczky A. A historical mistake: the aqueduct of Sylvius. *Neurosurg Rev.* 2004;27:224–5. doi:10.1007/s10143-004-0334-9.
17. Tubbs RS, Loukas M, Shoja MM, Shokouhi G, Oakes WJ. François Magendie (1783–1855) and his contributions to the foundations of neuroscience and neurosurgery. *J Neurosurg.* 2008;108:1038–42. doi:10.3171/JNS/2008/108/5/1038.
18. Von Luschka H. Die Adergeflechte des menschlichen Gehirnes: eine Monographie. Berlin: Georg Reimer; 1855.
19. Key A, Retzius MG. Studien in der Anatomie des Nervensystems und des Bindegewebes. Stockholm: Samson and Wallin; 1875.
20. Dezena RA. Atlas of endoscopic neurosurgery of the third ventricle. Basic principles for ventricular approaches and essential intraoperative anatomy. Cham: Springer International Publishing AG; 2017. doi: 10.1007/978-3-319-50068-3
21. Rhoton AL Jr. The lateral and third ventricles. *Neurosurgery.* 2002;51:S207–71.
22. Standring S. Gray's anatomy: the anatomical basis of clinical practice. Edinburgh: Churchill Livingstone; 2008.
23. Jannetta PJ. Gross (mesoscopic) description of the human trigeminal nerve and ganglion. *J Neurosurg.* 1967;26(1):109-11.
24. Resch KD, Perneczky A, Tschabitscher M, Kindel S. Endoscopic anatomy of the ventricles. *Acta Neurochir Suppl.* 1994;61:57-61.
25. Burtscher J, Dessl A, Maurer H, Seiwald M, Felber S. Virtual neuroendoscopy, a comparative magnetic resonance and anatomical study. *Minim Invasive Neurosurg.* 1999;42(3):113-7.
26. Matula C, Tschabitscher M, Kitz K, Reinprecht A, Koos WTh. Neuroanatomical details under endoscopical view- relevant for radiosurgery? *Acta Neurochir Suppl.* 1995;63:1-4.
27. King WA, Frazee JG, De Salles AAF. Endoscopy of the central and peripheral nervous system. New York: Thieme; 1998.
28. Romero ADCB, Aguiar PHP, Borchardt TB, Conci A. Quantitative Ventricular Neuroendoscopy

Performed on the Third Ventriculostomy: Anatomic Study. *Neurosurgery*. 2011 Jun; 68(2 Suppl Operative):347-54; discussion 353-4. doi: 10.1227/NEU.0b013e318211449a.

29. Jacobson S, Marcus EM. Meninges, ventricular system and vascular system. In: Jacobson S, Marcus EM. *Neuroanatomy for the neuroscientist*. New York: Springer; 2008. p. 399-407.

30. Rhoton AL. The lateral and third ventricles. *Neurosurgery*. 2002;51(suppl 1):209-72.

31. Timurkaynak E, Rhoton AL, Barry M. Microsurgical anatomy and operative approaches to the lateral ventricles. *Neurosurgery*. 1986;19(5):685-723.

32. Grunert P, Perneczky A, Resch KDM. Endoscopic procedures through the foramen interventriculare of Monro under stereotactical conditions. *Minim Invasive Neurosurg*. 1994;37(1):2-8.

33. Fujii K, Lenkey C, Rhoton AL. Microsurgical anatomy of the choroidal arteries: lateral and third ventricles. *J Neurosurg*. 1980;52(2):165-88.

34. Cuello LM, Gagliardi CE. Anatomía endoscópica del sistema ventricular. In: *Técnicas actuales en neurocirugía endoscópica*. Buenos Aires: Ediciones de la Guadalupe; 2007. p.95-106.

35. Lang J. Anatomy of the midline. *Acta Neurochir Suppl*. 1985;35:6-22.

36. Ernestus R-I, Krüger K, Ernst S, Lackner K, Klug N. Relevance of magnetic resonance imaging for ventricular endoscopy. *Minim Invasive Neurosurg*. 2002;45(2):72-7.

37. Loes DJ, Barloon TJ, Yuh WT, DeLaPaz RL, Sato Y. MR anatomy and pathology of the hypothalamus. *AJR Am J Roentgenol*. 1991;156(3):579-85.

38. Corrales M, Torrealba G. The third ventricle. Normal anatomy and changes in some pathological conditions. *Neuroradiology*. 1976;11(5):271-7.

39. Vinas FC, Dujovny N, Dujovny M. Microanatomical basis for the third ventriculostomy. *Minim Invasive Neurosurg*. 1996;39(4):116-21.

40. Çataltepe O. Endoscopic third ventriculostomy: indications, surgical technique, and potential problems. *Turk Neurosurg*. 2002;12:65-73.

41. Zohdi A, Ibrahim I. Variations in the site and size of third ventriculocisternostomy. *Minim Invasive Neurosurg*. 1998;41(4):194-7.

42. Lang J. Topographic anatomy of preformed intracranial spaces. *Acta Neurochir Suppl*. 1992;54:1-10.

43. Oka K, Go Y, Kin Y, Tomonaga M. An observation of the third ventricle under flexible fiberoptic ventriculoscope: normal structure. *Surg Neurol*. 1993;40(4):273-7.

44. Lang J. Surgical anatomy of the hypothalamus. *Acta Neurochir*. 1985;75(1-4):5-22.

45. Vinas FC, Panigrahi M. Microsurgical anatomy of the Lilliequist membrane and surrounding neurovascular territories. *Minim Invasive Neurosurg*. 2001;44(2):104-9.

46. Romero ADCB, Silva CE, Aguiar PHP. The distance between the posterior communicating arteries and their relation to the endoscopic third ventriculostomy in adults: An anatomic study. *Surgical Neurology International*, 2011;2:91. doi:10.4103/2152-7806.82373.

47. Denby CE, Vann SD, Tsvilis D, Aggleton JP, Montaldi D, Roberts N, Mayes AR. The frequency and extent of mammillary body atrophy associated with surgical removal of a colloid cyst. *Am J Neuroradiol*. 2009;30(4):736-43. doi: 10.3174/ajnr.A1424.

48. Dezena RA. Endoscopic third ventriculostomy. Classic concepts and a state-of-the-art guide. Cham: Springer International Publishing AG; 2020. doi: 10.1007/978-3-030-28657-6.