

# Current practices in temporal arachnoid cysts: a survey among Brazilian neurosurgeons

Raíssa Mansilla<sup>1</sup>, Tatiana Protzenko<sup>1</sup>, Marcelo Sampaio Pousa<sup>2</sup>, Clara Magalhães Paiva<sup>3</sup>, Gianpiero Tamburrini<sup>3</sup>, Antônio Rosa Bellas<sup>1</sup>

<sup>1</sup> Department of Pediatric Surgery, Division of Pediatric Neurosurgery; Fernandes Figueira National Institutes of Health for Women, Children, and Adolescents, Oswaldo Cruz Foundation (IFF-Fiocruz), Rio de Janeiro, Brazil

<sup>2</sup>Department of Pediatric Neurosurgery, Jesus Municipal Hospital; Rio de Janeiro, Brazil

<sup>3</sup>Pediatric Neurosurgery Unit, Institute of Neurosurgery, Catholic University Medical School, Rome, Italy

To whom correspondence should be addressed: Raíssa Mansilla, MD

e-mail: raissamansilla@gmail.com

Available at: <http://www.archpedneurosurg.com.br/>

**Introduction:** There has been no consensus for the best treatment strategy for TACs. The aim of this survey was to aggroup the different practices between Brazilian pediatric neurosurgeons in the management of a children with TAC Galassi Type II and III.

**Methods:** contributors answered a case questionnaire about TACs and select the answer that better reflect their conduct in asymptomatic or symptomatic patients (chronic headache, epilepsy and psychomotor retardation).

**Results:** all respondents confessed that had doubts about TACs and 59-75% was not satisfied only with brain MRI. Fundoscopy was the most required exam (28-35%), followed by EEG/VideoEEG (19-20%), ICP-NI (16%) and MRI CSF flowmetry (12-13%). For asymptomatic, 61-85% suggested follow-up with clinical, radiologic and fundoscopic control. Still, surgery was the choice for 61-70% in symptomatic patients. The preferred technique for TAC type II was endoscopic cysto-cisternostomy (32%) and for type III craniotomy and arachnoid cyst marsupialization (25%). Discussion: Since the past 14 years, more information has become available about the natural history of TACs and innovative technologies arises for its management helps. Treatment is still debated, but endoscopy is increasingly common and proved to be safe and effective.

**Conclusion:** modern technologies allow more security and subsidies to treatment chosen and even though for TAC Galassi type III open craniotomy still is preferred than endoscopic surgery, nowadays the least invasive treatment have been the choice for TAC Galassi Type II. The years of experience in endoscopy and the more availability of the tool into hospitals maybe contributed to this pattern change.

**Keywords:** temporal arachnoid cyst; survey; management; treatment, Brazil

## INTRODUCTION

With the advent and popularization of neuroimaging the prevalence of Temporal Arachnoid Cysts (TACs) – also referred to as middle or sylvian fissure arachnoid cysts - have been increased worldwide[1,2] and become a more common focus of discussion among specialists.

Although it can be an incidental finding and remain asymptomatic[3,4], typical associated symptoms have been reported in the literature, such as headache, epilepsy, psychomotor retardation, increased intracranial pressure and intracranial bleeding.[4-10] The propension to operate increased when the symptoms were associated to the radiological image. According to their size and degree of mass effect, Galassi et al (1982)[11] radiologic classified TACs in three types, ranging from small to enormous lesions with midline deviation. However, the cause-effect relationship of

these findings with clinical manifestations even remains difficult to be establish[12].

An interesting survey, published in 2008 by Tamburrini et al.[13], sought to achieve a European consensus of symptoms, complementary exams and surgical indications, as well as types of treatment in symptomatic and asymptomatic TACs. Fourteen years have passed since this publication and there is still no evidence to guide how these cysts should be treated.[14]

Thereby, a survey considering new investigative technologies and surgical techniques - and also Latin American specialists - was made to review the different practices between neurosurgeons in the management of asymptomatic or symptomatic children with TAC Galassi Type II and III, information not yet available in literature.

<http://www.archpedneurosurg.com.br/>

Received: 10 May 2022  
Accepted: 21 September 2022  
Published: 25 September 2022



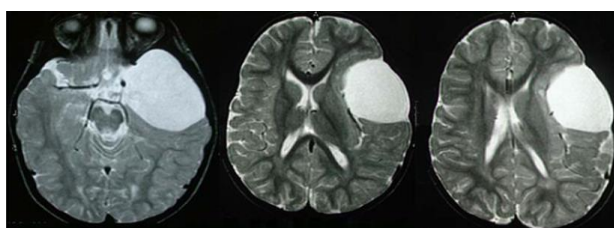
License terms



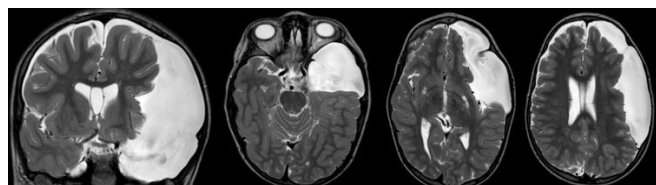
## Current practices in temporal arachnoid cysts: a survey among Brazilian neurosurgeons

### METHODS

Considering two clinical cases, one with a MRI with TAC Galassi type II (Figure 1) and other with type III (Figure 2), contributors were asked to answer a multiple-choice questionnaire and select the answer that better reflect their conduct in a 3-year-old-boy in different situations: no symptoms or symptomatic clinical situations (chronic headache, epilepsy and delayed milestones). The first question was what (and if) they would request to complement the MRI study, eventually indicating which diagnostic examination, between CT scan, electroencephalography (EEG), MRI with CSF flow study, PET and SPECT, lumbar puncture with manometry, non-invasive or invasive intracranial pressure monitoring and funduscopy. The second one was what would be the therapeutic proposal: clinical follow-up or surgical treatment. If they have chosen the conservative treatment, in the third question, responders were asked about how they would follow the patient: clinical, clinical and radiological or clinical, radiological and fundoscopic follow up. If they have chosen the surgical treatment, in the fourth question, contributors would choose which surgical technique fits better in each case and situation: I - craniotomy and arachnoid cyst marsupialization; II - craniotomy, arachnoid cyst marsupialization and removal of the cyst walls; III - pure endoscopic marsupialization of the arachnoid cyst; IV - endoscopic-assisted marsupialization of the arachnoid cyst; V- endoscopic cysto-cystostomy; VI - cysto-peritoneal shunt.



**Figure 1** - Case 1. A 3-year-old-boy with Temporal Arachnoid Cyst Galassi type II (image reproduced with permission of Tamburrini G)



**Figure 2** - Case 2. A 3-year-old boy with Temporal Arachnoid Cyst Galassi type III.

### RESULTS

Among 187 neurosurgeons were asked to participate to the survey and 61 completed the questionnaire (32%). Participants were mostly experienced neurosurgeons with more than 15 years of professional experience (57%), specialized in pediatric neurosurgery (65%), who had operated between one to ten arachnoid cysts in the last 5 years (64%). All respondents said they had doubts about the therapeutic management of a patient with arachnoid cyst, and the frequency of doubts was rated 11% as "always", 26% as "often", 46% as "sometimes" and 16% as "rarely".

**Table 1**- Profile of respondents

Characteristics	N	%
<b>Length of professional experience (years)</b>		
1 – 5	9	15
6 – 10	6	10
11 – 15	11	18
16 – 20	10	16
> 20	25	41
<b>Arachnoid cysts operated in the last 5 years</b>		
1 – 10	39	64
10 – 20	14	23
> 20	8	13
<b>Frequency of doubts in a patient with arachnoid cysts</b>		
Never	0	0
Rarely	10	16
Sometimes	28	46
Often	16	26
Always	7	11
<b>Fellow in Paediatric Neurosurgery</b>		
Yes, 1 year.	33	54
Yes, 6 months.	7	11
No.	21	34

Overall, more than half (59-75%) of the respondents reported not be satisfied only with brain MRI to propose a therapeutic plan for a child with temporal arachnoid cyst, suggesting further diagnostic evaluation, regardless symptoms or Galassi's classification (Table 2).

**Table 2**- Percentages of investigators suggesting further diagnostic evaluation

Suggested further diagnostic evaluation	Incidental diagnosis (%)	Chronic headache (%)	Seizures (%)	Psychomotor retardation (%)	Total (%)
Type II	59	90	95	89	83
Type III	75	87	95	89	87

## Current practices in temporal arachnoid cysts: a survey among Brazilian neurosurgeons

Ophthalmologic evaluation with fundoscopy was the most required exam (28-35%), followed by EEG or VideoEEG (19-20%), ICP-NI (16%) and MRI CSF flowmetry (12-13%). In a subgroup analysis, this prevalence order was found for patients with incidental diagnosis or psychomotor retardation. However, in patients with seizures, EEG (29-31%), fundoscopy (26-30%) and ICP-NI (12-15%) were the most requested exams. And, in chronic headache, fundoscopy (37%), ICP-NI (19%) and MRI CSF flowmetry (15%). The complete information about all suggested exams according to symptoms and Galassi classification was available in Table 3.

**Table 3-** Diagnostic exams required according to symptoms and Galassi classification

Diagnostic exam required	Incidental diagnosis	Chronic headache	Psychomotor retardation	Seizures	Total
<b>Type II</b>	%	%	%	%	%
Fundoscopy	33	30	26	26	28
EEG or videoEEG	17	11	19	29	19
ICP-NI	15	20	16	12	16
MRI CSF flowmetry	12	13	11	12	12
CT scan	13	14	10	10	11
PET/SPECT	7	5	11	5	7
CSF manometry	4	7	6	6	6
ICP-I	0	1	1	1	1
<b>Type III</b>	%	%	%	%	%
Fundoscopy	43	37	34	30	35
EEG or videoEEG	14	12	21	31	20
ICP-NI	15	19	17	15	16
MRI CSF flowmetry	16	15	12	11	13
CT scan	9	10	7	7	8
PET/SPECT	3	3	5	3	3
CSF manometry	1	3	2	2	2

For asymptomatic patients, more than 2/3 suggested (61-85%) clinical follow-up, with the majority indicating clinical, radiologic and fundoscopic control for both TAC Galassi type II and III. On the other hand, in symptomatic patients with TAC type II less than a half (33-49%) suggested conservative treatment, being these rates even lower in symptomatic patients with TAC type III (23-26%). For symptomatic patients, when conservative treatment was

chosen, 70-74% of the interviewers indicated clinical, radiologic and fundoscopic control as follow-up. All information about clinical follow-up was available on Table 4 and 5.

**Table 4-** Percentages of investigators suggesting clinical follow-up only

Clinical follow-up only	Incidental diagnosis (%)	Chronic headache (%)	Psychomotor retardation (%)	Seizure (%)
<b>Type II</b>	85	49	33	41
<b>Type III</b>	61	28	26	23
<b>Type II + III</b>	73	39	30	32

**Table 5-** Percentages of clinical follow-up control suggestions

Suggestion	Incidental diagnosis	Chronic headache	Psychomotor retardation	Seizures	Total
<b>Type II</b>	%	%	%	%	%
Clinical follow-up only	25	10	13	15	16
Clinical and radiological follow up	28	18	23	25	24
Clinical, radiological and fundoscopic follow up	41	67	52	44	51
Would not follow up / did not answer	6	5	12	16	10
<b>Type III</b>					
Clinical follow-up only	17	9	10	5	10
Clinical and radiological follow up	21	15	19	21	19
Clinical, radiological and fundoscopic follow up	61	74	70	72	69
Would not follow up / did not answer	1	2	1	2	1,5

Overall, surgical treatment was indicated in only 27% of asymptomatic patients with TAC. In contrast, for patients with chronic headache, psychomotor retardation and seizures, surgery was the choice, respectively, in 61, 70 and 68% of interviewed neurosurgeons. The preferred surgical option between the specialists for TAC Type II was endoscopic cysto-cisternostomy (32%), followed by endoscopic-assisted marsupialization of the arachnoid cyst (13%) and pure endoscopic marsupialization of the arachnoid cyst (12%). Moreover, for TAC Type III the elected technique was the craniotomy and arachnoid cyst marsupialization (25%), followed by endoscopic cysto-cisternostomy (23%) and cysto-peritoneal shunt (15%).

## Current practices in temporal arachnoid cysts: a survey among Brazilian neurosurgeons

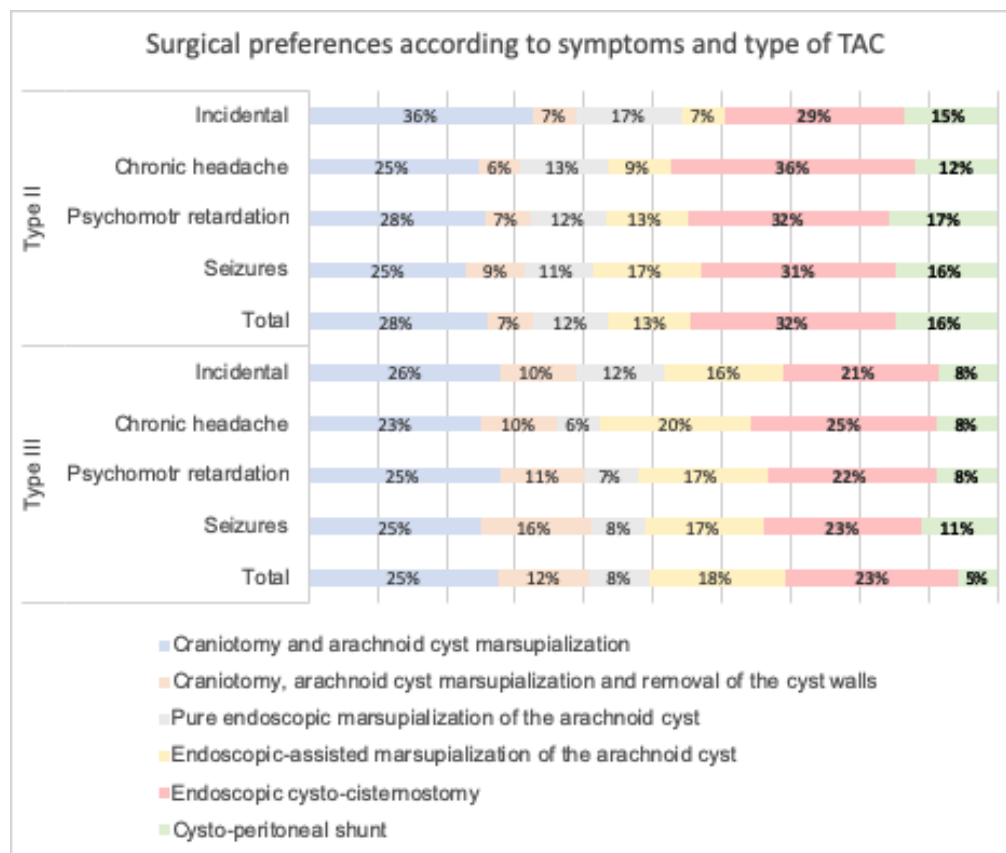


Figure 3- Surgical preferences according to symptoms and type of TAC

### DISCUSSION

Even for the most experienced neurosurgeons there has been no consensus for the best treatment strategy for TAC due to the arduous task to establish the direct relationship between radiological features and symptoms. In our survey – as far we know the first in Brazil – all neurosurgeons confessed that had doubts about the subject and approximately, 9 out of 10 neurosurgeons (87-95%), suggested an additional diagnostic evaluation before proposing a treatment for a child with symptomatic TAC Galassi II or III diagnosed by MRI.

On the other hand, for asymptomatic patients, 41% would not ask any further exam in a child with TAC Galassi Type II, but only 25% would do the same if it were a TAC Galassi Type III, suggesting that radiological difference in TAC is an isolated reason for treatment management changes in TAC. Tamburrini et al (2008)[13] have shown a similar result for the TAC Galassi II symptomatic patients, but in asymptomatic ones our interviewed suggested less additional exams (73 vs 59%).

A possible explanation for this difference is that more information has become available about the natural history of arachnoid cysts during the past 15 years. Al-Holou et al. (2010)[15] evaluated 111 patients who presented asymptomatic arachnoid cyst and observed that 10% enlarged and only 2,7% developed symptoms in a mean follow-up of 3.5 years (all of them diagnosed in the first year of life). Another study by Hall S et al (2019)[16] with 116 pediatric patients found 84 (72,4%) asymptomatic patients and none of them developed new symptoms during the 2.5-year follow-up period.

Regarding the further evaluation, although fundoscopy was the most requested exam in our population, its results should be interpreted with caution. Papilledema is the hallmark sign for intracranial hypertension (estimated specificity of 95%)[17], however, due to its low sensibility, its absence does not exclude the diagnosis [18-20].

The most likely explanation for this is that the development of papilledema requires a critical duration of intracranial pressure elevation. Another explanation is that some people require a low intracranial pressure to function

## Current practices in temporal arachnoid cysts: a survey among Brazilian neurosurgeons

normally, and symptoms could appear from slight elevations in intracranial pressure within the normal range, which may explain the absence of papilledema [19]. Helland CA et al. (2007)[21], studied the intracystic pressure in patients with TAC and showed a mean pressure of 131mmH2O for all Galassi cyst types, within the limits of what is considered normal ICP. These findings shows that other factors than the absolute pressure may also be the reason for symptoms of TAC.

In this context, a new noninvasive ICP monitoring method via surrogate ICP waveform (Brain4care®) has been increasingly used among Brazilian neurosurgeons. In this technology, a non-invasive sensor connected to a monitor running software is placed in contact with the temporoparietal region and converts the electrical signals generated by the skull's pulsation, reflecting real-time ICP information in graphs and, so, brain compliance given by the ratio  $p_2/p_1$  [22]. Although there is no study evaluating specifically its use in patients with TAC, our survey showed a common recommendation of the method, what could be explained by the several papers published in the last ten years showing the validation and effectiveness of the method. [22-27]

About treatment, only 27% of the participants of our survey indicate surgery for a patient with asymptomatic TAC. However, when the relationship between symptoms and TAC was established, more than 2/3 choose the surgical treatment. The number of participants suggesting surgery for a child with symptomatic TAC Galassi type II, in our study, was approximately the double in comparison with those with incidental diagnostic, the same proportion observed by Tamburrini G et al (2008) [13]. However, differently from this earlier survey[13], our results showed a current preference for endoscopic procedures in the treatment of TAC Galassi type II (craniotomy: 66,6 vs 35%; endoscopy: 57% vs 28.8%; shunt 6,6% vs 15%), which can be explained by the greater safety in the use of the technique during these years. However, in Galassi Type III cysts the preferred technique was craniotomy and arachnoid cyst marsupialization.

Given the many different opinions about how to surgically treat TACs, several studies have been made to list the advantages and disadvantages of each technique [28-32]. A recent meta-analysis[4] comparing efficacy and safety between neuroendoscopic fenestration, microsurgical fenestration and cystoperitoneal shunt for middle cranial fossa arachnoid cysts showed a high efficacy between the three methods, with no significant difference in rate of clinical symptoms improvement (90, 87 and 93%, respectively). However, while cystoperitoneal shunt showed a higher rate of long-term complications (15%) and reduced short-term ones (10%), microsurgical fenestration was the opposite, with lower long- and higher short-term rates of

complications (3% and 44%, respectively). Despite the known disadvantages, cystoperitoneal shunting may not even be the primary surgical modality, but it might be considered as a replacement therapy.

On the other hand, surgical complications are reduced in neuroendoscopic fenestration, suggesting that this one may be the first choice for TAC, even with a low rate of cyst reduction when compared with the other groups (73% vs 87-93%)[4]. These findings support the notion that clinical improvement is not influenced by post-operative cyst reduction and are in line with our expert's opinion. However, considering surgery is not necessary for all patients, the decision of surgical treatment for TACs needs cautiousness.

### CONCLUSIONS

This survey reflexes an accurate picture of what is going on in neurosurgical practice and demonstrates that the management of TAC still is controverser. Conservative treatment was often indicated for asymptomatic patients and symptomatic ones should be considered to surgery. New diagnostic and follow-up technologies currently allow greater security in supporting conservative treatment, even in larger cysts and, in the same way, brings more subsidies to indicate a surgical approach independently of cyst Galassi classification. Even though for larger cysts (TAC Galassi type III) neurosurgeons still preferred open craniotomy than endoscopic surgery, nowadays the least invasive treatment have been the choice for TAC Galassi Type II. The years of experience in endoscopy and the more availability of the tool into hospitals maybe contributed to this pattern change.

### LIMITATIONS

This survey had some serious limitations, including a low response rate, which was not representative of the SBNPed membership as no responders and members without listed email address may have had different attitudes than responders.

### ACKNOWLEDGMENTS

The authors would like to express their sincere gratitude to Gianpiero Tamburrini and many thanks for all the participants of Brazilian Pediatric Neurosurgery Society and for their collaboration in this survey.

## Current practices in temporal arachnoid cysts: a survey among Brazilian neurosurgeons

### DISCLOSURES

#### Ethical approval

This study was performed in line with the principles of the Declaration of Helsinki. Approval was granted by the local Ethics Committee

#### Consent for publication

The patient gave consent to use his information and images for publication.

#### Conflict of interest

The authors declare no conflicts of interest with respect to the content, authorship, and/or publication of this article.

#### Funding

This research received no specific grant from any funding agency in the public, commercial or not-for-profit sectors

### REFERENCES

- Kim BS, Illes J, Kaplan RT, Reiss A, Atlas SW. Incidental findings on pediatric MR images of the brain. *AJNR Am J Neuroradiol.* 2002 Nov-Dec;23(10):1674-7. PMID: 12427622; PMCID: PMC8185842.
- Weber F, Knopf H. Incidental findings in magnetic resonance imaging of the brains of healthy young men. *J Neurol Sci.* 2006 Jan 15;240(1-2):81-4. doi: 10.1016/j.jns.2005.09.008. Epub 2005 Oct 26. PMID: 16256141.
- Huang JH, Mei WZ, Chen Y, Chen JW, Lin ZX. Analysis on clinical characteristics of intracranial Arachnoid Cysts in 488 pediatric cases. *Int J Clin Exp Med.* 2015 Oct 15;8(10):18343-50. PMID: 26770437; PMCID: PMC4694337.
- Chen Y, Fang HJ, Li ZF, Yu SY, Li CZ, Wu ZB, Zhang YZ. Treatment of Middle Cranial Fossa Arachnoid Cysts: A Systematic Review and Meta-Analysis. *World Neurosurg.* 2016 Aug;92:480-490.e2. doi: 10.1016/j.wneu.2016.06.046. Epub 2016 Jun 17. PMID: 27319312.
- Lorenz M, Niedermaier N, Lowitzsch K. Arachnoid cyst and tension headache: symptom or accidental finding? *Schmerz.* 2002 Aug;16(4):304-7. German. doi: 10.1007/s004820100088. PMID: 12192439.
- Marin-Sanabria EA, Yamamoto H, Nagashima T, Kohmura E. Evaluation of the management of arachnoid cyst of the posterior fossa in pediatric population: experience over 27 years. *Childs Nerv Syst.* 2007 May;23(5):535-42. doi: 10.1007/s00381-006-0284-3. Epub 2007 Feb 13. PMID: 17295043.
- Pradilla G, Jallo G. Arachnoid cysts: case series and review of the literature. *Neurosurg Focus.* 2007 Feb 15;22(2):E7. doi: 10.3171/foc.2007.22.2.7. PMID: 17608350.
- Karabagli H, Etus V. Success of pure neuroendoscopic technique in the treatment of Sylvian arachnoid cysts in children. *Childs Nerv Syst.* 2012 Mar;28(3):445-52. doi: 10.1007/s00381-011-1632-5. Epub 2011 Nov 17. PMID: 22089324.
- Wester K. Intracranial arachnoid cysts--do they impair mental functions? *J Neurol.* 2008 Aug;255(8):1113-20. doi: 10.1007/s00415-008-0011-y. Epub 2008 Jul 28. PMID: 18677648.
- Tan Z, Li Y, Zhu F, Zang D, Zhao C, Li C, Tong D, Zhang H, Chen Q. Children With Intracranial Arachnoid Cysts: Classification and Treatment. *Medicine (Baltimore).* 2015 Nov;94(44):e1749. doi: 10.1097/MD.0000000000001749. PMID: 26554773; PMCID: PMC4915874.
- Galassi E, Tognetti F, Gaist G, Fagioli L, Frank F, Frank G. CT scan and metrizamide CT cisternography in arachnoid cysts of the middle cranial fossa: classification and pathophysiological aspects. *Surg Neurol.* 1982 May;17(5):363-9. doi: 10.1016/0090-3019(82)90315-9. PMID: 7089853.
- Mustansir F, Bashir S, Darbar A. Management of Arachnoid Cysts: A Comprehensive Review. *Cureus.* 2018 Apr 10;10(4):e2458. doi: 10.7759/cureus.2458. PMID: 29888162; PMCID: PMC5991924.
- Tamburrini G, Dal Fabbro M, Di Rocco C. Sylvian fissure arachnoid cysts: a survey on their diagnostic workout and practical management. *Childs Nerv Syst.* 2008 May;24(5):593-604. doi: 10.1007/s00381-008-0585-9. Epub 2008 Feb 28. Erratum in: *Childs Nerv Syst.* 2008 May;24(5):635. Del Fabbro, Mateus [corrected to Dal Fabbro, Mateus]. PMID: 18305944.
- Jafrani R, Raskin JS, Kaufman A, Lam S. Intracranial arachnoid cysts: Pediatric neurosurgery update. *Surg Neurol Int.* 2019 Feb 6;10:15. doi: 10.4103/sni.sni\_320\_18. PMID: 30815323; PMCID: PMC6383341.
- Al-Holou WN, Terman S, Kilburg C, Garton HJ, Muraszko KM, Maher CO. Prevalence and natural history of arachnoid cysts in adults. *J Neurosurg.* 2013 Feb;118(2):222-31. doi: 10.3171/2012.10.JNS12548. Epub 2012 Nov 9. PMID: 23140149.
- Hall S, Smedley A, Sparrow O, Mathad N, Waters R, Chakraborty A, Tsitouras V. Natural History of Intracranial Arachnoid Cysts. *World Neurosurg.* 2019 Jun;126:e1315-e1320. doi: 10.1016/j.wneu.2019.03.087. Epub 2019 Mar 18. PMID: 30898748.

## Current practices in temporal arachnoid cysts: a survey among Brazilian neurosurgeons

17. Sallam A, Abdelaal Ahmed Mahmoud M Alkhatip A, Kamel MG, et al. The Diagnostic Accuracy of Noninvasive Methods to Measure the Intracranial Pressure: A Systematic Review and Meta-analysis. *Anesthesia and Analgesia*. 2021 Mar;132(3):686-695. DOI: 10.1213/ane.0000000000005189. PMID: 32991330.
18. Rufai, S.R., Marmoy, O.R., Thompson, D.A. et al. Electrophysiological and fundoscopic detection of intracranial hypertension in craniosynostosis. *Eye* (2022). <https://doi.org/10.1038/s41433-021-01839-w>
19. Nazir S, O'Brien M, Qureshi NH, Slape L, Green TJ, Phillips PH. Sensitivity of papilledema as a sign of shunt failure in children. *J AAPOS*. 2009 Feb;13(1):63-6. doi: 10.1016/j.jaapos.2008.08.003. Epub 2008 Nov 20. PMID: 19022691.
20. Steffen H, Eifert B, Aschoff A, Kolling GH, Völcker HE. The diagnostic value of optic disc evaluation in acute elevated intracranial pressure. *Ophthalmology*. 1996 Aug;103(8):1229-32. doi: 10.1016/s0161-6420(96)30518-6. PMID: 8764791.
21. Helland CA, Wester K. Intracystic pressure in patients with temporal arachnoid cysts: a prospective study of preoperative complaints and postoperative outcome. *J Neurol Neurosurg Psychiatry*. 2007 Jun;78(6):620-3. doi: 10.1136/jnnp.2006.101865. Epub 2006 Dec 8. PMID: 17158556; PMCID: PMC2077978.
22. Mascarenhas S, Vilela GH, Carlotti C, Damiano LE, Seluque W, Colli B, Tanaka K, Wang CC, Nonaka KO. The new ICP minimally invasive method shows that the Monro-Kellie doctrine is not valid. *Acta Neurochir Suppl*. 2012;114:117-20. doi: 10.1007/978-3-7091-0956-4\_21. PMID: 22327675.
23. Cabella B, Vilela GH, Mascarenhas S, et al. Validation of a New Noninvasive Intracranial Pressure Monitoring Method by Direct Comparison with an Invasive Technique. *Acta neurochirurgica. Supplement*. 2016 ;122:93-96. DOI: 10.1007/978-3-319-22533-3\_18. PMID: 27165884.
24. Ballesterio MFM, Frigieri G, Cabella BCT, de Oliveira SM, de Oliveira RS. Prediction of intracranial hypertension through noninvasive intracranial pressure waveform analysis in pediatric hydrocephalus. *Childs Nerv Syst*. 2017 Sep;33(9):1517-1524. doi: 10.1007/s00381-017-3475-1. Epub 2017 Jun 16. PMID: 28623520.
25. Frigieri G, Andrade RAP, Dias C, Spavieri DL Jr, Brunelli R, Cardim DA, Wang CC, Verzola RMM, Mascarenhas S. Analysis of a Non-invasive Intracranial Pressure Monitoring Method in Patients with Traumatic Brain Injury. *Acta Neurochir Suppl*. 2018;126:107-110. doi: 10.1007/978-3-319-65798-1\_23. PMID: 29492543.
26. Gomes I, Shibaki J, Padua B, Silva F, Gonçalves T, Spavieri-Junior DL, Frigieri G, Mascarenhas S, Dias C. Comparison of Waveforms Between Noninvasive and Invasive Monitoring of Intracranial Pressure. *Acta Neurochir Suppl*. 2021;131:135-140. doi: 10.1007/978-3-030-59436-7\_28. PMID: 33839834.
27. de Moraes FM, Rocha E, Barros FCD, Freitas FGR, Miranda M, Valiente RA, de Andrade JBC, Neto FEAC, Silva GS. Waveform Morphology as a Surrogate for ICP Monitoring: A Comparison Between an Invasive and a Noninvasive Method. *Neurocrit Care*. 2022 Aug;37(1):219-227. doi: 10.1007/s12028-022-01477-4. Epub 2022 Mar 24. PMID: 35332426; PMCID: PMC8947812.28. Levy ML, Wang M, Aryan HE, Yoo K, Meltzer H. Microsurgical keyhole approach for middle fossa arachnoid cyst fenestration. *Neurosurgery*. 2003 Nov;53(5):1138-44; discussion 1144-5. doi: 10.1227/01.neu.0000089060.65702.03. PMID: 14580280.
29. Shim KW, Lee YH, Park EK, Park YS, Choi JU, Kim DS. Treatment option for arachnoid cysts. *Childs Nerv Syst*. 2009 Nov;25(11):1459-66. doi: 10.1007/s00381-009-0930-7. Epub 2009 Jun 18. PMID: 19536550.
30. Yang SH, Lee KS, Sung JH, Son BC, Jeun SS, Kang JK. Surgical decompression of supratentorial arachnoid cysts in pediatric patients younger than one year. *Pediatr Neurosurg*. 2008;44(6):465-70. doi: 10.1159/000172969. Epub 2008 Nov 17. PMID: 19018155.
31. Ali ZS, Lang SS, Bakar D, Storm PB, Stein SC. Pediatric intracranial arachnoid cysts: comparative effectiveness of surgical treatment options. *Childs Nerv Syst*. 2014 Mar;30(3):461-9. doi: 10.1007/s00381-013-2306-2. Epub 2013 Oct 27. PMID: 24162618.
32. Gangemi M, Seneca V, Colella G, Cioffi V, Imperato A, Maiuri F. Endoscopy versus microsurgical cyst excision and shunting for treating intracranial arachnoid cysts. *J Neurosurg Pediatr*. 2011 Aug;8(2):158-64. doi: 10.3171/2011.5.PEDS1152. PMID: 21806357.