

Ventriculo-gallbladder shunt: a case report of a neglected technique

Valdecir Boeno Spnazato Júnior¹, Aline Rabelo Rodrigues², Beatriz Pereira Vilela², Carolina Barcha Santos³, João Victor Carvalho da Paz⁴, Ricardo Santos de Oliveira⁵, Matheus Fernando Manzolli^{5,6} Ballesterero

¹ University of Vale do Sapucaí, Pouso Alegre, Brazil

² Jataí Federal University, Jataí, Brazil.

³ Araraquara University, Araraquara, Brazil.

⁴ CEUMA University, São Luis, Brazil.

⁵ Ribeirão Preto Medical School, University of São Paulo, Ribeirão Preto, Brazil

⁶ Department of Medicine, Federal University of São Carlos, São Carlos, Brazil

To whom correspondence should be addressed: Matheus Ballesterero, MD

e-mail: ballesterero@gmail.com

Available at:
<http://www.archpedneurosurg.com.br/>

Hydrocephalus is a common central nervous system (CNS) disorder in which there is an excess of cerebrospinal fluid within the cerebral ventricles, leading to their dilation. There are several pathologies that lead to this scenario: cerebral aqueduct stenosis, congenital malformations, cerebral neoplasms, cerebral hemorrhages, traumatic brain injury and meningitis, while the signs and symptoms differ according to age, underlying disease, malformations or associated injuries, and intracranial pressure level. The invasive treatment routinely performed for hydrocephalus is the insertion of a drainage system, known as a bypass. The present report describe a case of a 4-year-old patient with a history of using multiple ventricular shunts with multiple complications which had as a definitive treatment a ventriculogallbladder shunt (VGB) technique, and was asymptomatic after 2 years of follow-up. VGB has a great indication factor, does not present physiological changes due to its absorption of CSF, manifests fewer complications during its use, and is controlled by radiography and USG. However, it is currently used in cases of ventriculoperitoneal shunt (VP) failure. A VGB placement carries the same risk of all inherent complications that can occur with a VP, including malfunction and infection. It can be concluded that a VGB is underestimated by most physicians as it is not a conventional method. Despite this, it should be an alternative to be considered in case of refractory patients and in the absence of effectiveness of other types of shunts.

Keywords: Hydrocephalus; Neurosurgery; Ventriculoperitoneal Shunt; Ventriculo-gallbladder shunt

INTRODUCTION

Hydrocephalus is a common central nervous system (CNS) disorder in which there is an excess of cerebrospinal fluid within the cerebral ventricles, leading to their dilation and affecting individuals of any age range. There are several pathologies capable of causing hydrocephalus, such as cerebral aqueduct stenosis, congenital malformations such as Arnold-Chiari syndrome and spina bifida, cerebral neoplasms, cerebral hemorrhages, traumatic brain injury and meningitis. In addition, it is noteworthy that this condition involves possible injuries, neurological sequelae and evolution to death [1, 2].

From this perspective, the invasive treatment commonly performed is the insertion of a drainage system, known as shunt, in order to communicate the cerebral ventricles with another body cavity and thus allow for continuous drainage of CSF. The most common shunt systems are: ventriculoperitoneal (VP), ventriculoatrial (VA), ventriculopleural (VPL), ventriculo-sagittal (V-S) and ventriculo-gallbladder (VGB).

Examples of cavities include the peritoneal, right atrial, pleural, sagittal venous sinus and gallbladder cavities. Of these, the first three are the most commonly used, with VGB being an unconventional approach and underused as an appropriate therapy. However, in some situations



Ventriculo-gallbladder shunt: a case report of a neglected technique

conventional options cannot be used or complications may occur, such as recurrent infections, dysfunctions and inability to absorb CSF. In the meantime, VGB appears as an alternative treatment [2,3,4,5].

In the present case report, we describe a 4-year-old patient with a history of multiple ventricular shunts, which presented several complications and whose definitive treatment was made possible by the VGB shunt technique.

CASE REPORT

A 4 year-old girl, with a history of a 24-week preterm twin pregnancy. The first VP shunt was performed when she was one year old, with several complications. She was sent in three years ago for externalization of the system and an unsuccessful retrohepatic shunt attempt. Afterwards a ventriculoatrial shunt (VA) was performed, with the occurrence of ventriculitis by a *Staphylococcus*. A ventriculosagittal sinus shunt was performed, with an improvement that lasted for a month, followed by another dysfunction, and was therefore replaced by another VA, with a new infection and bacteremia.

After proper ventriculitis treatment, a VGB shunt was performed. The technique was performed with the help of a pediatric surgeon and was similar to a simple cholecystectomy. A 3 cm right subcostal incision was performed with the exposure of the gallbladder fundus, preserving the bile duct hilum. Subsequently, a 2-layer purse-string suture was performed in the vesicular fundus, with a hole remaining in the middle of the suture, through which the distal catheter of the shunt was inserted. The procedure was completed following the same technique of a small laparotomy. Cranial computed tomography and abdominal ultrasound are shown in figures 1, 2 and 3. Finally, the patient is asymptomatic after a 2-year follow-up (Fig 4).

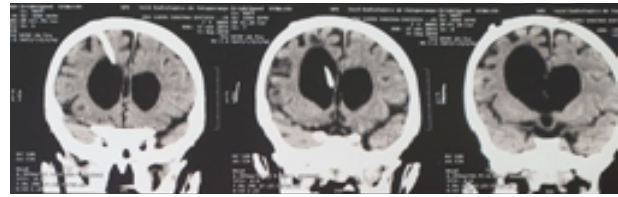


Figure 1- Pre-operative cranial computed tomography in sagittal section demonstrating hydrocephalus and proximal catheter inside ventricular system

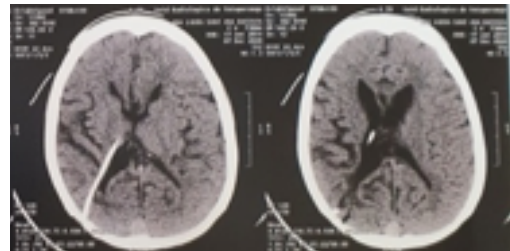


Figure 2- Post operative Computed tomography in sagittal section demonstrating improvement in hydrocephalus

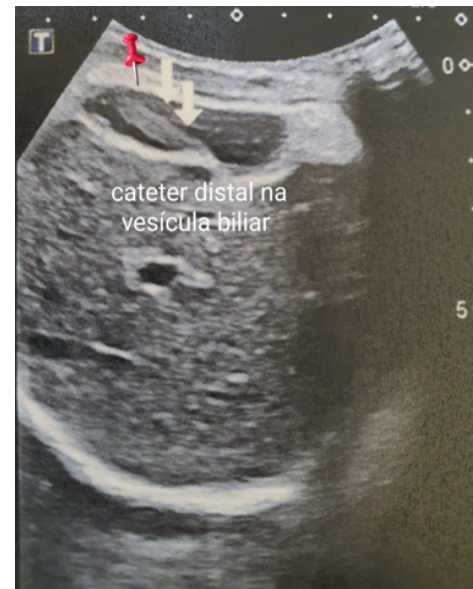

Figure 3- Abdominal ultrasound of the gallbladder, indicating the distal catheter for the ventriculogallbladder shunt (white arrow).

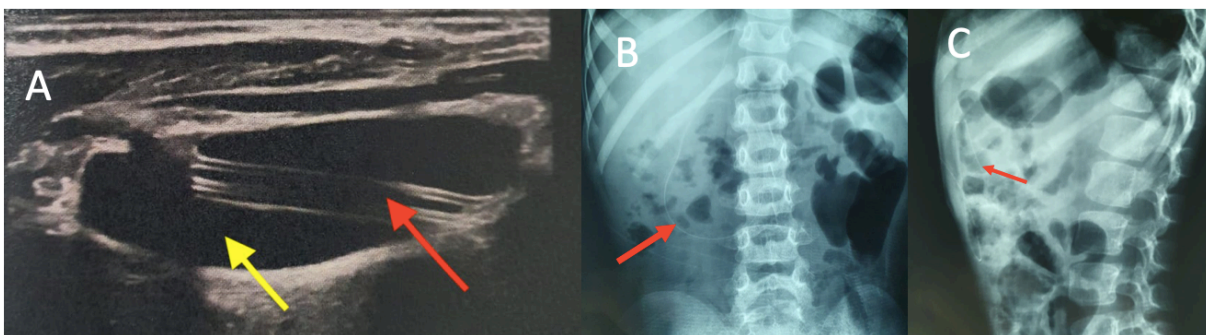


Figure 4- A- Abdominal ultrasound of the gallbladder, indicating the distal catheter (red arrow) and gallbladder lumen (yellow arrow). B - AP X-ray showing distal catheter (red arrow). C - Lateral view X-ray showing distal catheter (red arrow)

DISCUSSION

The first choice in hydrocephalus diversion is usually VP shunt. The system works through the law of hydrodynamics, in which the excess of CSF is drained from the ventricles to the peritoneal cavity through a drain and valves that make up the diversion structure. The patient in question had her first DVP at 1 year of age, with several complications and changes.

VP avoids micro and cardiovascular complications, when compared to atrial shunt, with easily controlled and less severe infections in most patients[6]. Some shunt complications include ventriculitis, subdural collections and abdominal pseudocysts, suture dehiscence, skin necrosis, peritoneum-intestinal adhesions, in addition to valve malfunction and other mechanical factors, while the main surgical issues occur in less than 2% of patients[7].

The patient also performed an externalization of the system and an unsuccessful retrohepatic shunt attempt. The ventricular catheter, when placed in an external reservoir, is called external ventricular drainage (EVD), and is the technique used in cases of contraindications for permanent shunts, intracranial pressure (ICP) monitoring, infections or intraventricular hemorrhages[1].

Another type of shunt is the VA, performed by jugular venous puncture, usually using Seldinger technique, with Doppler and ultrasound[8]. Its monitoring is essential due to the risk of infection, cardiac tamponade, venous dissection, cardiopulmonary changes, and disconnection of the distal catheter, which in many cases causes its tip to migrate to the right ventricle. This shunt is an alternative for cases in which the peritoneum is not functional to the technique or in complications from other shunts[4], in the present case report, a gram-positive Staphylococcal infection occurred.

Thus, the patient underwent VGB, remaining asymptomatic for two years. The shunt subtypes are similar in function and complications, while VGB does not present physiological changes due to its absorption of CSF, shows fewer complications during its use, and is controlled by radiography and USG. However, it is currently used in cases of VP failure.

The literature describes that patients undergoing DVB have already had other inserted shunts, due to infection recurrence, ascites or generalized inflammation of the peritoneum, as well as lack of CSF absorption and other VPD exchange factors (pleural, peritoneal). In addition, reoperation, weight, age and nutrition are poor prognostic factors[4]. Imaging studies should be performed to assess the presence and size of the gallbladder, while the possible conditions that preclude surgery include all infections or changes in abdominal viscera[9].

VGB technique involves the proximal shunt system and valve placed by the neurosurgeon in the standard way, followed by a tunneling device that is used to bring the distal catheter toward the abdominal incision. Before placing the catheter in the abdominal cavity, the distal end is modified to facilitate its attachment to the gallbladder wall afterwards being placed into the peritoneal cavity through an incision or port, depending on whether the exposure is open or laparoscopic, respectively[10].

CONCLUSION

VGB is a neglected technique to treat complicated and multiple shunted hydrocephalus. Pediatric neurosurgeons must be aware of this option when dealing with complex hydrocephalus patients.

DISCLOSURES

Ethical approval

This study was performed in line with the principles of the Declaration of Helsinki. Approval was granted by the local Ethics Committee

Consent to participate

The patient gave consent to use his information and images for research proposes.

Consent for publication

The patient gave consent to use his information and images for publication.

Conflict of interest

The authors declare no conflicts of interest with respect to the content, authorship, and/or publication of this article.

Funding

This research received no specific grant from any funding agency in the public, commercial or not-for-profit sectors

REFERENCES

1. Cunha AHGB da. Hidrocefalia na infância. Revista Brasileira de Neurologia e Psiquiatria. 2014;18(2):85–93.
2. Isaacs AM, Riva-Cambrin J, Yavin D, Hockley A, Pringsheim TM, Jette N, et al. Age-specific global epidemiology of hydrocephalus: Systematic review, meta-analysis and global birth surveillance. Cheungpasitporn W, editor. PLoS One. 2018 Oct 1;13(10):e0204926.

Ventriculo-gallbladder shunt: a case report of a neglected technique

3. Aldana PR, James HE, Postlethwait RA. Ventriculogallbladder shunts in pediatric patients. *J Neurosurg Pediatr.* 2008 Apr;1(4):284–7.
4. Girotti ME, Singh RR, Rodgers BM. The ventriculo-gallbladder shunt in the treatment of refractory hydrocephalus: a review of the current literature. *Am Surg.* 2009 Aug;75(8):734–7.
5. Hasslacher-Arellano JF, Arellano-Aguilar G, Funes-Rodríguez JF, López-Forcén S, Torres-Zapiain F, Domínguez-Carrillo LG. Derivación ventrículo-vesicular: una alternativa en el tratamiento de hidrocefalia. *Cir Cir.* 2016 May;84(3):225–9.
6. Gusmão S, Silveira RL, Filho GC, Arantes A. Aplicações clínicas da hidrodinâmica na derivação ventrículo-peritoneal. *Arq Bras Neurocir Brazilian Neurosurg.* 2000 Dec 11;19(04):179–83.
7. Jucá CEB, Lins Neto A, Oliveira RS de, Machado HR. Tratamento de hidrocefalia com derivação ventrículo-peritoneal: análise de 150 casos consecutivos no Hospital das Clínicas de Ribeirão Preto. *Acta Cir Bras.* 2002;17(suppl 3):59–63.
8. Morais ADS de, Mesquita MM, Santos T da S, Macedo Tavares CA da C, Miranda de Avellar L. Derivação ventriculoatrial percutânea – Nota técnica. *Arq Bras Neurocir Brazilian Neurosurg.* 2014 Mar 11;33(01):33–5.
9. Lyngdoh BT, Islam MS. Ventriculocholecysto shunt: a solution to recurrent shunt complications in comorbid post-tubercular hydrocephalus with tubercular adhesive peritonitis. *Acta Neurochir (Wien) [Internet].* 2012 Dec 4;154(12):2267–70.
10. West KW, Turner MK, Vane DW, Boaz J, Kalsbeck J, Grosfeld JL. Ventricular gallbladder shunts: An alternative procedure in hydrocephalus. *J Pediatr Surg.* 1987 Jul;22(7):609–12.